


# Quantification of temporomandibular joint space in patients with juvenile idiopathic arthritis assessed by cone beam computerized tomography

María Florinda Otero<sup>1</sup> | Pablo G. Tahoces<sup>2</sup> | Antonio Mera<sup>3</sup> | Michel Dalstra<sup>4</sup> |  
 Carlalberta Verna<sup>5</sup> | Thomas Klit Pedersen<sup>4,6</sup> | Troels Herlin<sup>7</sup> | Jorge Mira<sup>8</sup> 

<sup>1</sup>Health Research Institute of Santiago de Compostela (IDIS), Santiago de Compostela, Spain

<sup>2</sup>Departamento de Electrónica e Computación, Universidade de Santiago de Compostela, Santiago de Compostela, Spain

<sup>3</sup>Rheumatology Service, Hospital Clínico Universitario, Santiago de Compostela, Spain

<sup>4</sup>Section of Orthodontics, Department of Dentistry and Oral Health, Aarhus University, Aarhus, Denmark

<sup>5</sup>Department of Orthodontics and Pediatric Dentistry, University Center for Dental Medicine, Basel, Switzerland

<sup>6</sup>Department of Oral and Maxillofacial Surgery, Aarhus University Hospital, Aarhus, Denmark

<sup>7</sup>Department of Pediatrics, Aarhus University Hospital, Aarhus, Denmark

<sup>8</sup>Departamento de Física Aplicada and Instituto de Materiais (iMATUS), Universidade de Santiago de Compostela, Santiago de Compostela, Spain

## Correspondence

Jorge Mira, Departamento de Física Aplicada and Instituto de Materiais (iMATUS), Universidade de Santiago de Compostela, Santiago de Compostela E-15782, Spain.  
 Email: [jorge.mira@usc.es](mailto:jorge.mira@usc.es)

## Abstract

**Objective:** To describe a method to calculate the total intra-articular volume (interosseous space) of the temporomandibular joint (TMJ) determined by cone-beam computed tomography (CBCT). This could be used as a marker of tissue proliferation and different degrees of soft tissue hyperplasia in juvenile idiopathic arthritis (JIA) patients.

**Materials and Methods:** Axial single-slice CBCT images of cross-sections of the TMJs of 11 JIA patients and 11 controls were employed. From the top of the glenoid fossa, in the caudal direction, an average of 26 slices were defined in each joint ( $N=44$ ). The interosseous space was manually delimited from each slice by using dedicated software that includes a graphic interface. TMJ volumes were calculated by adding the areas measured in each slice. Two volumes were defined:  $V_{e-i}$  and  $V_i$ , where  $V_{e-i}$  is the interosseous space, volume defined by the borders of the fossa and  $V_i$  is the internal volume defined by the condyle. An intra-articular volume filling index (IF) was defined as  $V_{e-i}/V_i$ , which represents the filling of the space.

**Results:** The measured space of the intra-articular volume, corresponding to the intra-articular soft tissue and synovial fluid, was more than twice as large in the JIA group as in the control group.

**Conclusion:** The presented method, based on CBCT, is feasible for assessing interosseous joint volume of the TMJ and delimits a threshold of intra-articular changes related to intra-articular soft tissue proliferation, based on differences in volumes. Intra-articular soft tissue is found to be enlarged in JIA patients.

## KEYWORDS

cone-beam computed tomography, imaging, inflammation, juvenile idiopathic arthritis, TMJ

## 1 | INTRODUCTION

Juvenile idiopathic arthritis (JIA) is characterized by an inflammatory condition in synovial joints without any known cause and with the onset before the age of 16.<sup>1</sup> The temporomandibular joint (TMJ) is a bilateral synovial articulation between the mandible and the glenoid fossa of the temporal bone. TMJ involvement is frequently seen in JIA patients. Among them, the reported prevalence has ranged from 17% to 87% depending on the methods used for diagnosis, JIA subtype and the population studied.<sup>2-6</sup>

The TMJ has an upper and a lower compartment separated by an articular disc. The synovial membrane covers the intra-articular capsular surfaces. Thus, the intra-articular volume of the TMJ would be expected to yield information about a possible increase in the synovial tissue volume, thereby indirectly expressing the impact of the arthritis and, therefore, could be considered to provide an outcome measure in the progression and treatment of TMJ involvement.

Routinely, evaluation of the synovial joints is generally based on a clinical examination and imaging of the joints. Laboratory parameters are used to support arthritis activity assessment. The amount of synovial tissue can be anticipated to be related to the severity and duration of former active arthritis.<sup>7</sup>

Several reports suggest that magnetic resonance imaging (MRI) should play an important role in the diagnosis and assessment of TMJ arthritis and bone deformations in children with JIA.<sup>3,5,8-11</sup> Contrast enhanced MRI is currently the most informative imaging modality, as it allows visualization of both the active inflammatory disease as well as the extent of structural damage in the TMJ. However, there remains great variability in the acquisition and interpretation of TMJ MRI. An international, multidisciplinary expert group was formed within the Outcome Measures in Rheumatology (OMERACT) network to develop MRI scoring systems for JIA (JAMRI working group), with a dedicated subgroup for developing the TMJ-specific scoring system (JAMRIS-TMJ). They use semiquantitative grades. With this, they try to establish an injury protocol so that they have a common interpretation in the different countries.<sup>12</sup>

Nevertheless, MRI has some limitations, including the high cost, worse spatial resolution than computed tomography (CT) techniques, long scan time and the need for sedation, particularly in young children. Moreover, the use of a contrast medium is in many cases necessary in order to depict inflammation<sup>13</sup> and must be avoided in patients with renal insufficiency or hypersensitivity towards contrast medium.

The advantages of the CBCT technique are a lower radiation dose than for conventional medical CT, the ability to image small volumes on certain systems, and the higher image resolution<sup>14</sup> than MRI. Scan time ranges from 5 to 8 s, which also makes it feasible for small children. Several studies refer to CBCT as a technique for TMJ hard tissue assessment.<sup>14-20</sup>

The present paper is aiming to expand the possibilities of CBCT in the dental field. When using radiographs, a compromise must be found: on the one hand, their potential radiation danger; on the other, the dose is linked to image quality and this may not be lowered

so far that it jeopardizes the diagnostic outcome of a radiographic procedure. In a recent work we have tried to reinforce the image of CBCT to improve the visualization of the TMJ.<sup>21</sup> We have previously worked on qualitative imaging and now, with this work, on quantitative imaging of the TMJ and volume calculations.

In this line, an indirect quantitative measure of the enlargement of the synovium, using CBCT, might increase the possibilities of the assessment of the disease severity and could constitute an objective parameter to help in the evaluation of treatments.

The objective of the present study is to present and evaluate a CBCT-based method for an indirect determination of the volumes of the intra-articular soft tissue (capsule, synovium, disc and synovial fluid) and measuring the inter-osseous joint volume in order to compare the volumes of the TMJ between JIA patients and healthy controls.

## 2 | MATERIALS AND METHODS

### 2.1 | Patients studied

The project was registered at the Danish Data Protection Agency, registration number 2016-051-000001.

In this retrospective study, the study group ( $n=11$ ) consisted of patients diagnosed with JIA according to the ILAR criteria<sup>22</sup> referred by the Pediatric Rheumatology Clinic at the Aarhus University Hospital (Denmark) to the Regional Specialist Craniofacial Clinic - Section of Orthodontics at the Department of Dentistry and Oral Health of the University of Aarhus, for examination, monitoring and treatment of TMJ involvement and dento-facial deviation. The gender distribution was nine females and two males and the mean age ( $\pm$ SD) was 11.9 ( $\pm$ 2.4) years. In the original records of this group we found that there were patients annotated with a bilateral affection ( $n=4$ ) and patients with unilateral affection ( $n=7$ ).

We observed that in the medical records of these patients the clinicians showed suspicions of the involvement of only one TMJ or both. In fact, they introduced notes indicating whether only one TMJ was affected or both. In the present study we have chosen to keep this classification, although it did not bias our study.

The indication for CBCT in the patients was based on the following clinical findings: reduced chewing function, decreased maximum-opening capacity, reduced condylar translation and mandibular range of mobility and clear sign of asymmetric growth. CBCT scans were performed after the clinical examination.

The members of the control group ( $n=11$ ) were selected from cases where CBCT was indicated due to complicated orthodontic treatment, that is, retention of teeth or other factors, where JIA and other craniofacial abnormalities were excluded.

The gender distribution was eight females and three males, and the mean age ( $\pm$ SD) was 11.7 ( $\pm$ 2.3) years. The selection of the 11 patients and controls was based on the availability of files and not on any power calculation.

## 2.2 | Image acquisition

The CBCT images were acquired with a NewTom 3G CBCT scanner (3G, QR, Verona, Italy) at 110 kVP with a voxel dimension of  $0.30 \times 0.30 \times 0.36 \text{ mm}^3$ . A single  $360^\circ$  rotation, 36 s scan, comprising 360 single projections, using the 12-inch field of view, was taken for each patient.

The images obtained were stored in a DICOM (Digital Imaging and Communications in Medicine standard for distributing medical images regardless of scanner) and anonymized for further analysis in our laboratory. All cases include the TMJ as part of the acquired volume. The TMJ was manually segmented by an expert using custom design software tailored to the specific characteristics of this scenario.

## 2.3 | Data processing and volume assessment

The anatomical parts of interest for this study can be shown from a CBCT scan from an axial view (Figure 1). Although the soft tissue area measurement cannot be performed directly by CBCT, inter-osseous spaces can be outlined from the axial slices and their sizes automatically calculated. This task was carried out by using an image processing software developed by our team. The software allowed for visualization in the axial, coronal and sagittal projections and included contrast adjustment, selection of volumetric region of interests (ROI)s and the

possibility of free manual tracing for the segmentation of irregular areas in the image. Thus, once an axial slice was chosen, it was possible to perform manual tracings of the contour of the regions to be segmented and label each segmented region before storage. Moreover, all manual tracings were delineated using a tablet with a digital pencil to suitably achieve this operation.

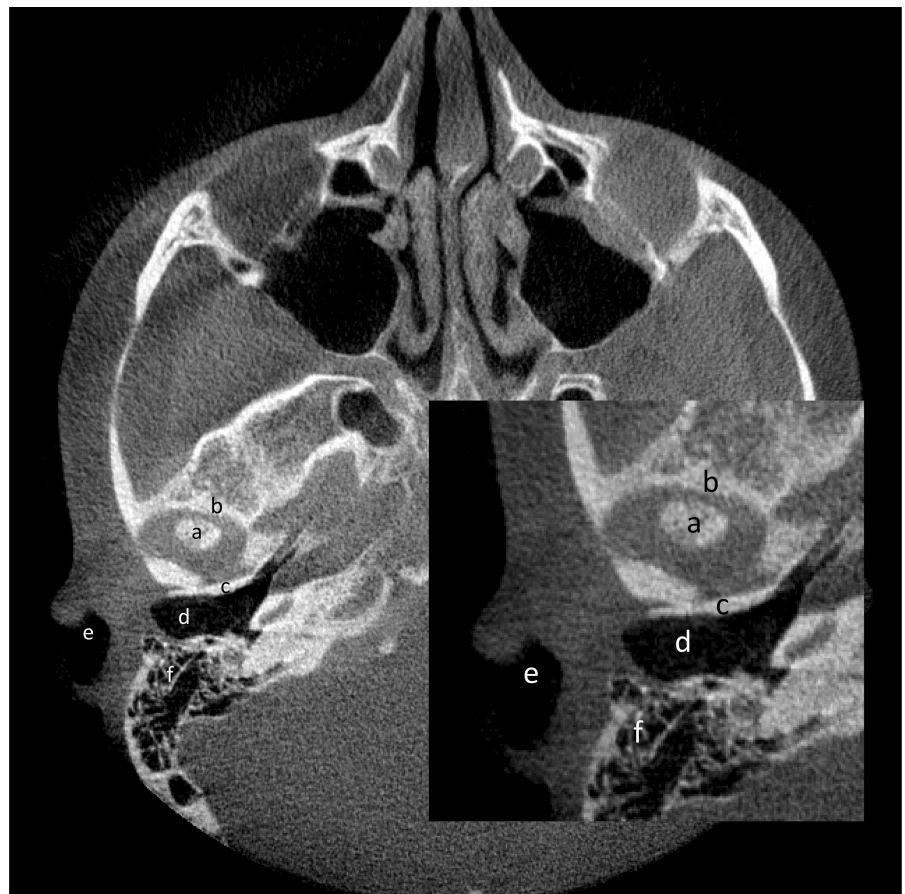In summary, the procedure performed was as follows:

- (i) From each axial slice  $k$ , two different areas were delineated:  $A_{ek}$ , the area of the joint space, limited by the extraarticular, surrounding bone;  $A_{ik}$ , the area of the bony condylar head (Figure 2).
- (ii) The total volumes associated with the inter-osseous space ( $V_{e-i}$ ), and with bony condylar head ( $V_i$ ) (Figure 3) were calculated over the total slice set, by means of the following expressions:

$$V_i = ST \sum_{k=1}^{n_i} A_{ik}$$

$$V_{e-i} = ST \sum_{k=1}^{n_e} (A_{ek} - A_{ik})$$

where  $n_i$  and  $n_e$  represent the number of slices where  $V_{e-i}$  and  $V_i$  were respectively outlined by manual tracing and ST was the slice thickness extracted from the DICOM headers of each imaging file (in this study 0.36 mm). Figure 4 shows a three-dimensional rendering of the volumes calculated above.



**FIGURE 1** Region of interest (ROI) in an axial slice from CBCT. Radiological description of the anatomical parts of the joint: (a) Mandibular condyle of the TMJ, (b) Preglenoid process (temporal bone), (c) Postglenoid process (temporal bone). Anatomical areas used to identify the TMJ in an axial slice: (d) Eustachian tube, (e) External auditory canal, (f) Mastoid process.

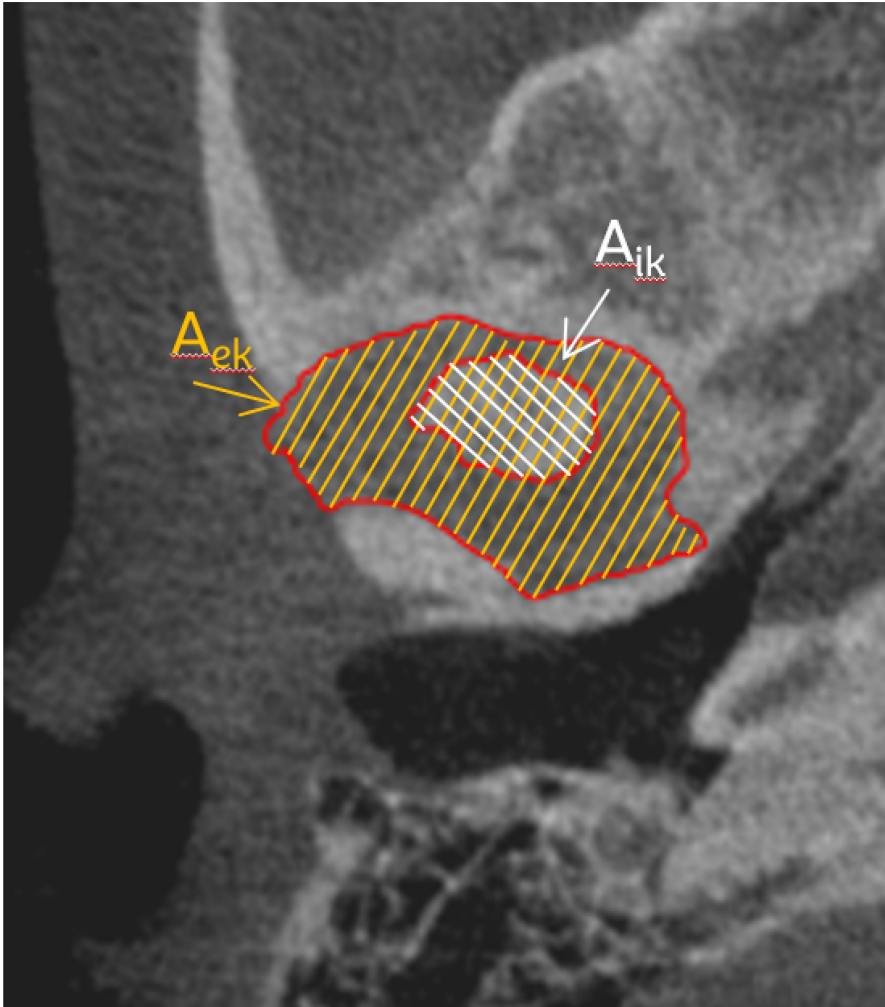


FIGURE 2 The two areas of interest in a random slice corresponding to the area of joint space limited by the outer bone tissue ( $A_{ek}$ ) and to the area of the condylar head ( $A_{ik}$ ).

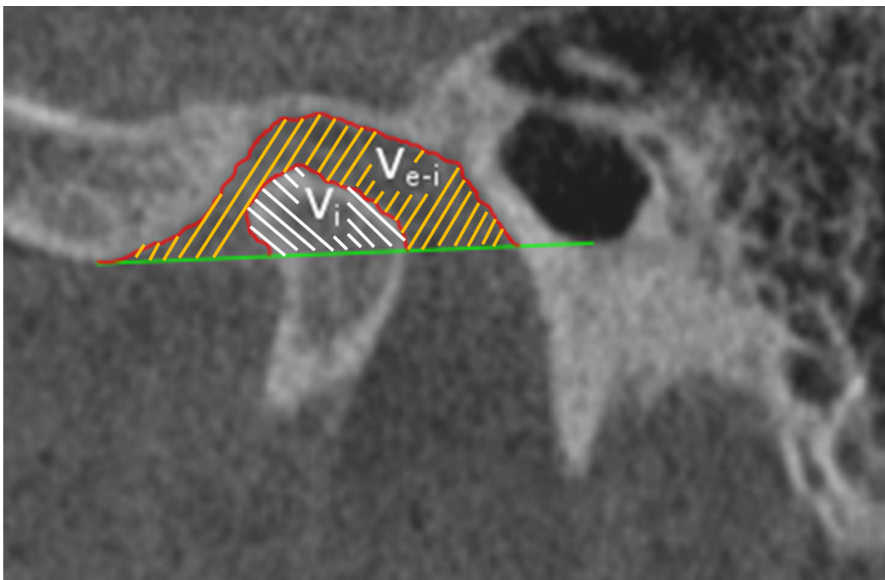
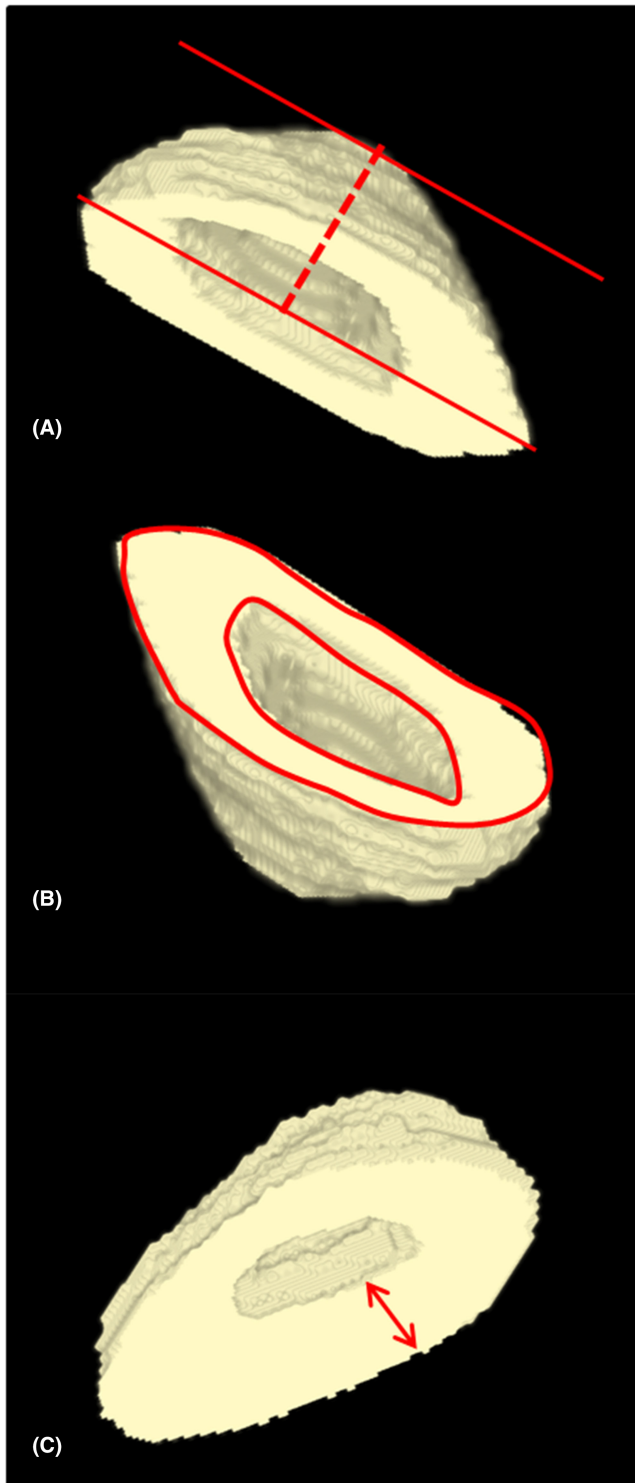


FIGURE 3 Lower part of the ROI demarcation in a sagittal view. A slice of the studied volumes ( $V_{e-i}$  and  $V_i$ ) are indicated.



**FIGURE 4** 3D graphic rendering of the volumetric model. (A) Upper and lower limits of the ROI in the 3D model. (B) The two borders with both interfaces were outlined manually. (C) From this segmentation, the software calculates the volume corresponding to the joint space, marked with an arrow.

(iii) Finally, taking both volumes as a reference, we define the index of filling of the intra-articular space of the TMJ, the intra-articular volume filling index, IF, as:

$$IF_{\text{index}} = \frac{(V_{e-i})}{(V_i)}$$

In this way, the higher the soft tissue volume, the higher  $IF_{\text{index}}$ . The division by  $V_i$  acts as a normalization factor, to scale the different sizes of the patients.

The evaluation of the effect of the operator on the variance in the manual segmentation method was performed by duplicating some randomly selected segmentations.

The statistical comparison of the joint volumes was performed using a non-parametric independent-samples Mann-Whitney U-test due to the small number of samples in the groups. Thus, the description analysis for all data included the median and the interquartile range, IQR (Q1-Q3).

### 3 | RESULTS

We have calculated both volumes ( $V_{e-i}$  and  $V_i$ ) for each of the 11 JIA patients and 11 healthy controls. The statistical analysis (Table 1) shows that the amount of soft tissue present in the joint space ( $V_{e-i}$ ) on both the right and left sides has a statistically significant difference between the JIA group and the healthy controls.

In contrast, the measured condylar bony part of the joint ( $V_i$ ) keeps reasonably stable values for control cases. This statistical result marks the strength of our method, as it indicates that  $V_i$  is a good basal reference parameter for the methodology that we are proposing here, because there is no statistical difference between JIA patients and controls for  $V_i$  volumes ( $P > .25$  for both sides). Furthermore, it is seen that we can measure the inter-osseous space, discovering a high difference between the JIA patients and the controls for  $V_{e-i}$  volumes, with a statistical significance (low  $P$  values for both sides,  $P < .001$ ).

If we analyze the values in the table, we also observe that the median of  $V_{i\_left}$  is almost twice than that of  $V_{i\_right}$  (509 vs. 280, a factor of 1.8) for the JIA group, which is not the case for the healthy group (338 vs. 288, a factor of 1.2). If we analyze the quartiles (Q1 and Q3) and calculate the IQR, the difference is not so high: 287 for  $V_{i\_left}$  and 258 for  $V_{i\_right}$  in the JIA group. If we do the same calculations for the healthy group, we have IQR values of 225 for  $V_{i\_left}$  and 213 for  $V_{i\_right}$ . That is, we have more dispersion in the JIA patients than in the healthy ones (which was to be expected), and also higher values of Q1 and Q3. The reason for this is that there are some JIA patients with relatively high  $V_{i\_left}$  values compared to  $V_{i\_right}$ , and this distorts the mean values. Specifically, one of the patients is very asymmetrical, with a large difference between the two sides.

The individual IF indexes (for the right and left side) of the 11 patients and 11 controls are represented in Figure 5 (just to evaluate differences between sides, we kept the original subdivision in the group affected by JIA, as indicated in the previous clinical records). From this figure, we can establish a criterion, defined by the quadrant  $IF_{\text{right}} < 2.4 - IF_{\text{left}} < 2.4$ , where none of the JIA patients is located,

	JIA (11 patients)	Controls (11 healthy persons)	U-test (P value)
	Median (Q1–Q3)	Median (Q1–Q3)	
$V_{e-i}$ right (mm <sup>3</sup> )	1235 (954–1902)	482 (396–676)	<.001
$V_i$ right (mm <sup>3</sup> )	280 (233–491)	288 (224–437)	.922
$V_{e-i}$ left (mm <sup>3</sup> )	1227 (849–1667)	598 (410–650)	<.001
$V_i$ left (mm <sup>3</sup> )	509 (298–585)	338 (213–438)	.309

Note: On the one hand, the Mann–Whitney U-test for the osseous part ( $V_i$ ) shows high values of  $P$  ( $P > .25$ ), indicating that it is a good basal reference parameter. On the other hand, the differences in the interosseous part ( $V_{e-i}$ ) present high variations with important statistical significance ( $P < .001$ ). This indicates that the proposed method visualizes the consequences of inflammatory involvement of the TMJ in patients with JIA.

TABLE 1 Comparison of the joint volumes in the JIA and control groups.

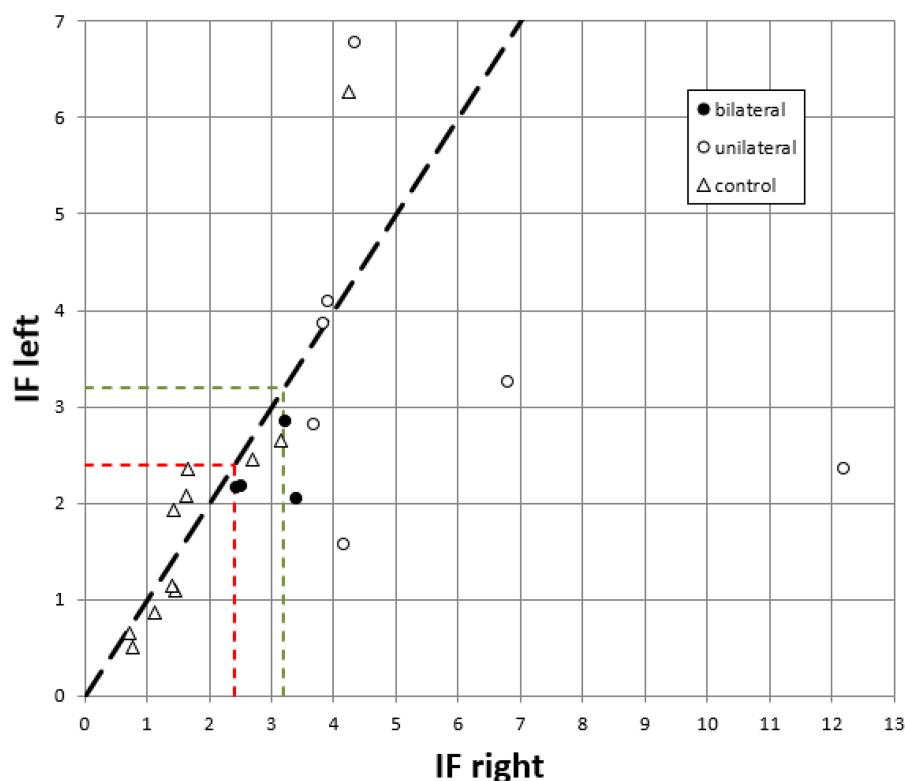


FIGURE 5 Distribution of both sides of the intra-articular filling indexes. The red and green dashed lines indicate possible areas of reference for the identification of healthy TMJs.

whereas eight controls fall within it (Beta error = 0.00). If the quadrant is expanded to  $IF_{right} < 3.2 - IF_{left} < 3.2$ , then 10 of the 11 controls fall within it, and only two individuals of the JIA group (Beta error = 0.18). These two individuals of the JIA group are, in fact, in a regime close to a healthy situation (in the framework described by Figure 5), which may be due to the fact that they were not in the active phase at the moment of the CBCT measurement. We found one outlier in the control group with IF values far outside this area.

Therefore, this procedure seems to define a rough approximation to a boundary to identify healthy TMJs versus the JIA-affected ones.

## 4 | DISCUSSION

Histopathologically, joint involvement in JIA is characterized by hypertrophic inflammatory synovitis with cellular infiltration,

proliferation of blood vessels and cartilage degeneration.<sup>23</sup> Magnetic resonance imaging (MRI) allows visualization of the inflamed synovial membrane<sup>24–26</sup> and, since the 90's, several quantification methods have been proposed by Ostergaard et al. to assess synovial volumes in humans by MRI in several joints other than the TMJ.<sup>7,27,28</sup> They concluded that synovial membrane volumes can be determined by MRI with a maximal analytical error of approximately 20%, which is enough to discriminate from synovial volumes if a joint either clinically active, clinically inactive or healthy.

Resnick et al.<sup>29</sup> have developed and validated a simple and reliable method for quantifying TMJ synovial enhancement in JIA patients using gadolinium-enhanced MRI. Its objective was to distinguish the TMJs with pathologic synovitis from those with normal background synovial enhancement using MRIs with gadolinium. ROIs were selected within the superior TMJ, and pixel intensity values were measured to compute an enhancement ratio (ER) index.

They observed that ER values of 1.55 differentiates between a TMJ with synovitis and an unaffected one. Thereby, they concluded that their method could be used to quantify inflammation in arthritis and in any disease state. Using a similar procedure, Ma et al.<sup>30</sup> found that 20% of TMJs that had mild synovitis did not demonstrate hypertrophy of the synovium and determined that synovial thickening was not a reliable marker for disease.

The above-cited papers demonstrated that using quantitative information extraction techniques from images, as a marker for the analysis and follow-up of TMJ-related diseases, proves very useful. In our case, we have explored the possibility of using similar techniques on CBCT images. The main motivations for this have been the relative accessibility of such an imaging modality in the dental setting and the availability of TMJ files obtained from this technique.

It is important to note that, for the extraction of quantitative information, in both cases (MRI and CBCT), ROIs were delineated in areas of the analyzed images. However, the kind of data that was acquired changed. In the case of MRI, pixel intensity values were measured.<sup>29</sup> These values were related with inflammation. However, in our case (using CBCT images), it was the total number of pixels, within the chosen location, that was related with inflammation or hyperplasia. Thereby, in MRI, the data to be recorded is related to the activity associated with that region, whereas in CBCT what is collected is connected to the region's volumes to be analyzed.

The use of volume for joint pathology analysis is not new. Arici et al.<sup>31</sup> have used the difference in volume of the TMJ to evaluate the result of orthopaedic treatment in patients without a diagnosis of JIA. They analyzed the space joint of the TMJ using a methodology similar to ours and divided the TMJ components in the following: volume of the glenoid fossa (GF), volume of the condyle (CON), volume of the anterior joint space (AJS) and volume of the posterior joint space (PJS). The main difference from our method is that the segmentation of the area of interest is done in only three axial slices from the multiplanar reconstruction images and, in healthy patients, without signs of inflammation or TMJ disorders.

In our work we have tried to go beyond the approach of Arici et al. We focused on the whole volume, in order to extract a measurable quantity ( $V_{e-t}$ ) to include as much of the tissue as possible. Arici et al. have found statistically significant differences in the volume of the PJS in the TMJs of these healthy patients without arthritis.<sup>31</sup> With this, we obtained a score that reflects the amount of hyperplastic tissue into the TMJ. Thereby, our proposal would be to use the inter-osseous volume as a quantitative marker of TMJ deformation.

In fact, we have calculated an estimation of the inter-osseous joint volume in TMJs affected by JIA, achieved by outlining the joint space on CBCT images, and we have compared it with TMJs from healthy patients. These retrospective images belong to a sample of patients with a long-standing diagnosis of JIA. We know from the literature that the TMJ is a silent joint and that JIA is a disease that occurs with peaks of activity. Indeed, we have found that the space volume was statistically significantly higher in TMJs affected by arthritis than in the control group.

A limitation related to the retrospective nature of the study is the fact that the CBCT examinations of the study were selected through

an imaging database rather than consecutively through a systemic monitoring system. In this database we have possibly found different states of TMJ involvement in the patients affected by JIA, which could explain the cases of the two individuals close to the boundary. Also, the selection of the 11 patients and controls was based on the availability of files and not on any power calculation, and this (and the relatively small group size) could add a potential limitation, as this could have introduced bias in our findings, as these patients might not be a good representation, making it hard to make clear-cut conclusions. Besides these limitations, we note that an inflamed synovium may expand the space beyond the classic osseous boundaries. In these cases, there could be room for errors in the measurement, as we are not measuring outside the bone limits of the TMJ. Future research should compare the technique hereby proposed in CBCT and MRI to assess possible deviations from truth due to expanded synovia.

Finally, we want to highlight that we are presenting here a method to estimate the volume of an unhealthy TMJ in a group of children. With this, we can obtain a measurable amount (number of pixels) of space. In a well-designed sample (greater number of patients, age, gender, different TMJ arthritis affectations, different treatments, etc.) this methodology could be used as an opportunistic screening tool<sup>32</sup> allowing to identify patients affected by JIA in early stages.

#### AUTHOR CONTRIBUTIONS

MFO contributed to the concept and design of the study, she worked the images and contributed to the analysis and interpretation of the data and preparation and drafting of the article. PGT supervised the imaging work and also worked the statistics and analyzed and interpreted the data, he also contributed to the preparation and drafting of the article. AM provided the rheumatologic approach, he also contributed to the analysis and critical interpretation of the data. MD managed the data and permissions and was involved in the statistics. CV supervised aspects concerning the TMJ and critically reviewed the drafting of the article. TKP provided the TMJ pathology approach, he also contributed to the analysis and critical interpretation of the data and to the preparation and drafting of the article. TH provided the rheumatologic and TMJ approach, he supervised and critically reviewed the drafting of the article, he also contributed to the analysis and interpretation of the data. JM led the work: he contributed to conceive and design the study, to the analysis and interpretation of the data and wrote the paper.

#### ACKNOWLEDGEMENTS

We wish to acknowledge Julián Lamas-Rodríguez, from 1000shapes GmbH (Germany), for a critical reading of this manuscript.

#### CONFLICT OF INTEREST STATEMENT

The authors declare no conflict of interest.

#### DATA AVAILABILITY STATEMENT

The data underlying this article will be shared on reasonable request to the corresponding author.



## ORCID

Jorge Mira  <https://orcid.org/0000-0002-6024-6294>

## REFERENCES

- Damasio MB, Malattia C, Martini A, Tomà P. Synovial and inflammatory diseases in childhood: role of new imaging modalities in the assessment of patients with juvenile idiopathic arthritis. *Pediatr Radiol*. 2010;40(6):985-998.
- Twilt M, Schulten AJM, Verschure F, Wisse L, Prah-Andersen B, van Suijlekom-Smit LW. Long-term follow-up of temporomandibular joint involvement in juvenile idiopathic arthritis. *Arthritis Rheum*. 2008;59(4):546-552. Available from: <http://www.ncbi.nlm.nih.gov/pubmed/18383409>
- Argyropoulou MI, Margariti PN, Karali A, et al. Temporomandibular joint involvement in juvenile idiopathic arthritis: clinical predictors of magnetic resonance imaging signs. *Eur Radiol*. 2009;19(3):693-700.
- Billiau AD, Hu Y, Verdonck A, Carels C, Wouters C. Temporomandibular joint arthritis in juvenile idiopathic arthritis: prevalence, clinical and radiological signs, and relation to dentofacial morphology. *J Rheumatol*. 2007;34(9):1925-1933. Available from: <http://www.ncbi.nlm.nih.gov/pubmed/17696265>
- Küseler A, Pedersen TK, Gelineck J, Herlin T. A 2 year Followup study of enhanced magnetic resonance imaging and clinical examination of the temporomandibular joint in children with juvenile idiopathic arthritis. *J Rheumatol*. 2005;32(1):162-169.
- Assar E, de la Fuente S, Angenete O, et al. Juvenile idiopathic arthritis and the temporomandibular joint: a comprehensive review. *J Craniomaxillofac Surg*. 2016;44(5):597-607.
- Ostergaard M, Hansen M, Stoltenberg M, et al. Magnetic resonance imaging-determined synovial membrane volume as a marker of disease activity and a predictor of progressive joint destruction in the wrists of patients with rheumatoid arthritis. *Arthritis Rheum*. 1999;42(5):918-929.
- Müller L, Kellenberger CJ, Cannizzaro E, et al. Early diagnosis of temporomandibular joint involvement in juvenile idiopathic arthritis: a pilot study comparing clinical examination and ultrasound to magnetic resonance imaging. *Rheumatology (Oxford)*. 2009;48:680-685.
- Kellenberger CJ, Abramowicz S, Arvidsson L, Kirkhus E, Tzaribachev N, Larheim TA. Recommendations for a standard magnetic resonance imaging protocol of temporomandibular joints in juvenile idiopathic arthritis. *J Oral Maxillofac Surg*. 2018;76:2463-2465.
- Vaid YN, Dunnington FD, Royal SA, Beukelman T, Stoll ML, Cron RQ. Imaging of the temporomandibular joint in juvenile idiopathic arthritis. *Arthritis Care Res (Hoboken)*. 2014;66(1):47-54. Available from: <http://www.ncbi.nlm.nih.gov/pubmed/24106204>
- Tzaribachev N, Fritz J, Horger M. Spectrum of magnetic resonance imaging appearances of juvenile temporomandibular joints (TMJ) in non-rheumatic children. *Acta Radiol*. 2009;50(10):1182-1186.
- Tolend M, Doria AS, Meyers AB, et al. Assessing the reliability of the OMERACT juvenile idiopathic arthritis magnetic resonance scoring system for temporomandibular joints (JAMRIS-TMJ). *J Clin Med*. 2021;10(18):4047. doi:10.3390/jcm10184047
- Küseler A, Pedersen TK, Herlin T, Gelineck J. Contrast enhanced magnetic resonance imaging as a method to diagnose early inflammatory changes in the temporomandibular joint in children with juvenile chronic arthritis. *J Rheumatol*. 1998;25(7):1406-1412.
- Scarfe WC, Farman AG. What is cone-beam CT and how does it work? *Dent Clin N Am*. 2008;52(4):707-730.
- Al-koshab M, Nambiar P, John J. Assessment of condyle and glenoid fossa morphology using CBCT in south-east Asians. *PLoS One*. 2015;10(3):e0121682.
- Petersson A. What you can and cannot see in TMJ imaging—an overview related to the RDC/TMD diagnostic system. *J Oral Rehabil*. 2010;37(10):771-778.
- Wiese M, Wenzel A, Hintze H, et al. Influence of cross-sectional temporomandibular joint tomography on diagnosis and management decisions of patients with temporomandibular joint disorders. *J Orofacial Pain*. 2011;25(3):223-231.
- Cevitanes LHS, Hajati AK, Paniagua B, et al. Quantification of condylar resorption in temporomandibular joint osteoarthritis. *Oral Surgery, Oral Med Oral Pathol Oral Radiol Endodontology*. 2010;110(1):110-117.
- Krishnamoorthy B, Mamatha N, Kumar VA. TMJ imaging by CBCT: current scenario. *Ann Maxillofac Surg*. 2013;3(1):80-83.
- Barghan S, Tetradis S, Mallya S. Application of cone beam computed tomography for assessment of the temporomandibular joints. *Aust Dent J*. 2012;57(Suppl 1):109-118.
- Otero MF, García Tahoces P, Mera A, Mira J. TMJ contrast enhancement in CBCT images using a new algorithm. *Acta Radiol Open*. 2022;11(1):1-6.
- Petty R, Southwood T, Manners P, et al. International league of associations for rheumatology classification of juvenile idiopathic arthritis. *J Rheumatol*. 2004;31(2):390-392.
- Ording Muller LS, Humphries P, Rosendahl K. The joints in juvenile idiopathic arthritis. *Insights Imaging*. 2015;6:275-284.
- Frick MA, Wenger DE, Adkins M. MR imaging of synovial disorders of the knee: an update. *Radiol Clin North Am*. 2007;45:1017-1031.
- Hemke R, Maas M, Van Veenendaal M, et al. Contrast-enhanced MRI compared with the physical examination in the evaluation of disease activity in juvenile idiopathic arthritis. *Eur Radiol*. 2014;24(2):327-334.
- Larheim TA. Role of magnetic resonance imaging in the clinical diagnosis of the temporomandibular joint. *Cells Tissues Organs*. 2005;180(1):6-21.
- Ostergaard M. Different approaches to synovial membrane volume determination by magnetic resonance imaging: manual versus automated segmentation. *Br J Rheumatology*. 1997;36(11):1166-1177.
- Ostergaard M, Hansen M, Stoltenberg M, Lorenzen I. Quantitative assessment of the synovial membrane in the rheumatoid wrist: an easily obtained MRI score reflects the synovial volume. *Br J Rheumatol*. 1996;35(10):965-971.
- Resnick CM, Vakilian PM, Breen M, et al. Quantifying temporomandibular joint synovitis in children with juvenile idiopathic arthritis. *Arthritis Care Res*. 2016;68(12):1795-1802.
- Ma GM, Amirabadi A, Inarejos E, et al. MRI thresholds for discrimination between normal and mild temporomandibular joint involvement in juvenile idiopathic arthritis. *Pediatr Rheumatol Online J*. 2015;13:53.
- Arici S, Akan H, Yakubov K, Arici N. Effects of fixed functional appliance treatment on the temporomandibular joint. *Am J Orthod Dentofacial Orthop*. 2008;133(6):809-814.
- Pickhardt PJ, Summers RM, Garrett JW, et al. Opportunistic screening: radiology scientific expert panel. *Radiology*. 2023;307(5):e222044.

**How to cite this article:** Otero MF, Tahoces PG, Mera A, et al. Quantification of temporomandibular joint space in patients with juvenile idiopathic arthritis assessed by cone beam computerized tomography. *Orthod Craniofac Res*. 2023;00:1-8. doi:10.1111/ocr.12702