

## Combined endodontic-periodontal treatment of a palatogingival groove

### Abstract:

The palato-gingival groove is a developmental anomaly that predisposes the tooth involved to a severe periodontal lesion. These grooves often present a challenge to the clinicians as diagnosing and treatment planning that requires an interdisciplinary approach.

This case report describes the successful management of a right maxillary lateral incisor with a deep palatal groove in combination with a extensive periodontal pocket, and necrosis pulp of the tooth involved. A collaborative management was carried out using a combination endodontic treatment, periodontal therapy, odontoplasty, and periodontal regenerative procedure with protein complex of the enamel matrix derivative (Emdogain). Despite an apparently poor prognosis of the tooth, the successful healing of the lesion was achieved. This report is also discussed the rationale behind of the treatment modalities.

### Key words:

Interdisciplinary approach, palatal groove, periodontal regenerative techniques.

## Introduction

The area of the maxillary incisors is an embryologically committed area. The palatogingival groove is one developmental anomaly that may occur in this area. This anomaly usually starts in the central fossa of the maxillary central and lateral incisors, crosses the cingulum, and proceeds disto-apically to varying distances (1-4). The anomaly is not limited in extent and can vary in depth and complexity (5).

The predominant location of this anomaly is the palatal surface of the maxillary lateral incisors (6-8). Its incidence is 2.8% to 8.5% (3,4,9), although the literature contains studies with isolated values of up to 18.0% or 44.6%, with some authors suggesting a possible ethnic/racial relationship (10).

The etiology of the palatogingival groove remains controversial. Some have described it as an infolding of the enamel organ and the epithelial sheath of Hertwig, resulting in a mild form of dens invaginatus (2,3). Others argue that it is an attempt by the tooth germ to form another root (11,12), while a third view is that the cause is related to altered genetic mechanisms (13).

Clinically, this developmental defect provides a route for bacteria to penetrate the periodontal ligament, which makes the tooth susceptible to progressive periodontal inflammation along the groove. Sometimes in teeth with a radicular groove, the periodontium is connected to the pulp. This communication occurs, in most cases, through the presence of accessory canals (1). Thus, pulp-periodontal bacterial contamination can travel in both directions with relative ease. This is why symptoms in patients range from a localized deep periodontal pocket to a periodontal abscess, and they test positive or negative according to the pulp nerve involvement. The prognosis of teeth with a palatogingival groove is therefore variable and depends mainly on the

1  
2 location of the groove, severity of the periodontal problem, accessibility of the defect,  
3 and type of groove (shallow/deep, long/short) (6).  
4

5  
6 Therapeutic modalities for this disease have been numerous and varied over the  
7  
8 years, although they have not always been as successful as expected. This article  
9  
10 describes a case involving a maxillary lateral incisor that underwent combined  
11  
12 endodontic-periodontal treatment and achieved proper healing of the affected tissues.  
13  
14

### 15 16 17 18 19 **Case report** 20

21  
22 A 40-year-old woman was referred to our clinic by her dentist because of a fistula and  
23  
24 periradicular radiolucency associated with the upper right lateral incisor. The patient  
25  
26 reported that she suffered an injury 5 years earlier in the right anterior maxilla, but the  
27  
28 injury had not caused any dental problems to date. She did not report pain and noted the  
29  
30 appearance of the fistula about 1 week earlier.  
31  
32  
33

34  
35  
36 Extraoral and intraoral clinical examination revealed a fistulous process between  
37  
38 teeth 1.2 and 1.3 in the alveolar mucosa (Fig. 1A). First, a periapical radiograph was  
39  
40 taken and two radiolucent lesions were seen: one at the apical level and the other at the  
41  
42 lateral level (Fig. 1B). Fistulography with introduction of a gutta percha cone through  
43  
44 the sinus tract showed a lateral radiolucent area (Fig. 1C). Careful inspection of the  
45  
46 image revealed a parapulpal radiolucent line extending along the root to the apical third,  
47  
48 which would correspond to the palatogingival groove. Pulp vitality tests with Endo-Ice  
49  
50 spray and a dental pulp tester showed negative results for both, while the adjacent teeth  
51  
52 responded normally. Thus, the diagnosis shifted toward pulp necrosis of the affected  
53  
54 tooth. The patient reported sensitivity to percussion, while mobility was negative.  
55  
56  
57  
58  
59  
60 Periodontal probing was physiological along the gingival sulcus, with the exception of a  
61  
62  
63  
64  
65

1 10-mm narrow periodontal pocket located on the palatal surface of the tooth,  
2 concomitant with the palatogingival groove (Figs. 1D, 2). The homologous contralateral  
3 incisor was inspected because the anomaly often affects both sides of the arch; in this  
4 case, however, tooth 2.2 seemed to be normal.  
5  
6  
7  
8  
9

10 Cone-beam computed tomography (CBCT) was performed to clarify the  
11 diagnosis. This helped to visualize any communication between the pulp and  
12 periodontium that may relate to the affected tissues, determine the precise depth and  
13 length of the radicular groove, and elucidate the internal anatomy of the canal. The  
14 CBCT scan (Fig. 3) confirmed that the endodontic injury and periodontal lesion were  
15 apparently independent and without communication. In axial sections, we could see that  
16 the palatogingival groove was not connected to the pulp space.  
17  
18  
19  
20  
21  
22  
23  
24  
25  
26  
27

28 Based on the clinical and radiographic evidence, the lesion was diagnosed as  
29 post-traumatic pulp necrosis and localized periodontitis secondary to a radicular groove,  
30 with no apparent relationship between them. Although the prognosis of the tooth was  
31 questionable, the patient chose to undergo treatment after the possible complications  
32 were explained. The treatment plan established was as follows: endodontic treatment of  
33 tooth 1.2 with subsequent removal of the palatogingival groove and regeneration of the  
34 periodontal lesion performed with proteins derived from enamel matrix (Emdogain;  
35 Biora AB, Malmö, Sweden).  
36  
37  
38  
39  
40  
41  
42  
43  
44  
45  
46  
47

48 First, basic periodontal treatment was performed to improve the conditions of  
49 the oral cavity, and the patient was provided with appropriate hygiene guidelines. A root  
50 canal treatment was then performed. This was done in two phases. On the first day, after  
51 access, we achieved patency of the canal with K hand files to #20 (Fig. 4A), and the  
52 canal was instrumented with a ProTaper Next X3 (Dentsply Maillefer, York, PA) to an  
53  
54  
55  
56  
57  
58  
59  
60  
61  
62  
63  
64  
65

1 apical diameter of 30 mm, irrigating abundantly throughout the process with 5.25%  
2 sodium hypochlorite. A bifurcation was found in the canal on the apical level. Two  
3  
4 weeks later, before final closure of the canal, the canal was irrigated with 5.25% sodium  
5  
6 hypochlorite and 17% EDTA liquid, activating both with Endoactivator (Dentsply Tulsa  
7  
8 Dental Specialties, Tulsa, OK). The Thermafil #30 system (Tulsa Dental Products) was  
9  
10 used to fill the canal, and Pulp Canal Sealer (SybronEndo, Orange, CA) was used as the  
11  
12 sealer and applied in abundant quantities to achieve lateral branching. Finally, a final  
13  
14 composite reconstruction was performed (Fig. 4B).  
15  
16  
17  
18  
19

20 One week later, the patient underwent surgical treatment to eliminate the  
21  
22 palatogingival groove and address the periodontal problem. Intrasulcular incisions were  
23  
24 made to lift a flap that allowed access to the palatine bone defect. Direct visualization  
25  
26 allowed observation of a 10-mm groove depth and showed that the injury  
27  
28 communicated with a vestibular cortical fenestration (Fig. 5A, B). Granulation tissue  
29  
30 was removed and sent for histological analysis, and the results were consistent with a  
31  
32 granulomatous lesion. We performed an odontoplasty of the groove using a Periojet  
33  
34 drill (Fig. 5C), followed by treatment of the exposed root surfaces with curettage and  
35  
36 ultrasound. Because bone loss was extensive and exposed dentin was present on the root  
37  
38 surfaces, we decided to use Emdogain in an attempt to secure apposition of the new  
39  
40 acellular cementum, which binds strongly to dentin and in turn induces regeneration of  
41  
42 the periodontal ligament and alveolar bone. The protein complex of the enamel matrix  
43  
44 derivative was applied (Fig. 5D), and a single membrane was placed in the buccal area  
45  
46 defect (Fig. 6A). The defect was sutured with Goretex using a vertical mattress pattern  
47  
48 and simple stitches (Fig. 6B, C).  
49  
50  
51  
52  
53  
54  
55

56 Antibiotic therapy with 500 mg of metronidazole (Flagyl) three times per day  
57  
58 was prescribed for 1 week and soft brushing was suggested, avoiding the surgical site  
59  
60  
61  
62  
63  
64  
65

1  
2  
3  
4  
5  
6  
7  
8  
9  
10  
11  
12  
13  
14  
15  
16  
17  
18  
19  
20  
21  
22  
23  
24  
25  
26  
27  
28  
29  
30  
31  
32  
33  
34  
35  
36  
37  
38  
39  
40  
41  
42  
43  
44  
45  
46  
47  
48  
49  
50  
51  
52  
53  
54  
55  
56  
57  
58  
59  
60  
61  
62  
63  
64  
65

for the first 48 h. The use of 0.12% chlorhexidine gluconate was recommended to supplement oral hygiene measures.

The sutures were removed at 15 days, and healing was evident. We reviewed the patient at 3, 6, and 9 months. At 9 months, photographs and radiographs were taken and a CBCT control examination was performed (Fig. 7A-D). The CBCT scan showed that almost complete healing of the lesions had occurred.

## **Discussion**

We have reported a case involving a palatal gingival groove on the palatal surface of a maxillary lateral incisor with severe periodontal problems in connection with pulp necrosis. The treatment was challenging and required an interdisciplinary approach.

The evidence for such endoperiodontal lesions illustrates the relationship between the pulpal and periodontal organ (15,16). The radicular groove is an ideal trap for bacterial accumulation and thus for the occurrence of periodontal damage. Everett et al. (3) found that in patients with severe radicular grooves, the root dentin harbors numerous cracks along the fault that allow communication between the groove and pulp. Gao et al. (17) noted that the accessory foramina and lateral canals located along the floor or wall of the groove are additional means of bacterial invasion of the pulp. Considering also the exposed dentinal tubules, due to inflammatory resorption resulting from the periodontal lesion, there are other routes for the passage of bacteria from the groove to the pulp organ (17).

In most cases, therefore, a primary periodontal lesion with secondary involvement of the pulp is present. However, it is also possible that a primarily infected

1 root canal results in a severe periodontal defect by spread of the bacteria to the apex and  
2 posterior coronal progression. Thus, the apical defect will join the lesion from the  
3  
4 groove, completing periodontal breakdown along the full length, resulting in a  
5  
6 questionable prognosis (12). Moreover, there is the possibility that the pulpal and  
7  
8 periodontal lesions are unrelated, their etiologies are different, and they simply coincide  
9  
10 in time (18), as we believe happened in the present case.  
11  
12  
13

14  
15 Because of the potential variability in double bacterial invasion, diagnosis of  
16  
17 conditions involving the palatogingival groove is typically complex. An investigation  
18  
19 by electron microscopy of 14 lateral maxillary incisors with radicular grooves showed  
20  
21 that in most cases, an accessory foramen was present in an invagination (17), making it  
22  
23 the primary means of communication between the pulp and periodontium. However, our  
24  
25 case differed from this. In our patient, pulp necrosis was associated with a previous  
26  
27 trauma, and we confirmed a lack of communication between the pulp and periodontium  
28  
29 using CBCT.  
30  
31  
32  
33  
34

35  
36 Today, the use of dental CBCT can overcome many of the limitations of  
37  
38 conventional radiography by producing 3D images that allow complete evaluation of  
39  
40 the anatomy and spatial relationships between the pathology and anatomical structures  
41  
42 (19). For apical periodontitis, this diagnostic technique is significantly more accurate  
43  
44 and sensitive than conventional radiography (20) because it is able to identify periapical  
45  
46 bone destruction associated with endodontic infections before such destruction is  
47  
48 identifiable in an X-ray (21). CBCT also allows for differentiation of separate defects in  
49  
50 bone and cortical bone; both were present in the case described here. In endodontics,  
51  
52 CBCT has been shown to be a reliable tool in assessing the degree of root curvature  
53  
54 (22). Furthermore, in cases of anatomical and morphological anomalies requiring  
55  
56 endodontic treatment, such as a palatogingival groove, CBCT is a useful element in  
57  
58  
59  
60  
61  
62  
63  
64  
65

1 assessment and treatment planning (23). In this case, it was important because we  
2 decided to perform obturation of the root canal system with classic gutta due to a lack of  
3  
4 communication between the pulp and periodontal space.  
5  
6

7  
8 Thus, using these new technologies and relating the data from the clinical  
9  
10 history, we could conclude that we were dealing with an endoperiodontal injury without  
11  
12 communication. From this diagnosis, we established an interdisciplinary treatment plan  
13  
14 involving both endodontic and periodontal therapy.  
15  
16

17  
18 Many alternative treatments for radicular groove problems have been presented  
19  
20 in the literature. Such treatments are usually related to the severity of the injury. They  
21  
22 include management with gingivectomy or subgingival scaling and root planing if the  
23  
24 groove is mild (2,3), placement of an amalgam restoration (24) or glass ionomer (1) in  
25  
26 mild cases or deep defects, granulation tissue removal through a flap (12), elimination  
27  
28 of the defect at the level of crestal bone using rotatory instruments (referred to as  
29  
30 “saucerization”) (3,11,12) with or without guided tissue regeneration techniques (25),  
31  
32 intentional extraction of a problematic tooth to achieve complete removal of the groove,  
33  
34 and subsequent reimplantation (33), orthodontic extrusion, and exodontia (3,12). All of  
35  
36 these techniques can be performed with or without appropriate treatment of the root  
37  
38 canal system, as the case demands.  
39  
40  
41  
42  
43  
44  
45

46 Although root canal treatment is not necessary in all cases of palatogingival  
47  
48 grooves, its importance should not be ignored. One goal in achieving endodontic  
49  
50 treatment success is removing pulp tissue residue, microorganisms, and toxins from the  
51  
52 root canal (26). To achieve this, we emphasize the fundamental role of irrigation.  
53  
54

55 Today, we know that the use of irrigation is vital in this type of treatment; however, to  
56  
57 reach maximum effectiveness, the irrigant solutions reportedly must be activated (27).  
58  
59  
60  
61  
62  
63  
64  
65

1  
2  
3  
4  
5  
6  
7  
8  
9  
10  
11  
12  
13  
14  
15  
16  
17  
18  
19  
20  
21  
22  
23  
24  
25  
26  
27  
28  
29  
30  
31  
32  
33  
34  
35  
36  
37  
38  
39  
40  
41  
42  
43  
44  
45  
46  
47  
48  
49  
50  
51  
52  
53  
54  
55  
56  
57  
58  
59  
60  
61  
62  
63  
64  
65

Another critical point in endodontics is the 3D filling and sealing around the root canal system. Although lateral condensation remains the most commonly used technique (28), it is not always the best obturation technique because of the lack of adaptation to the canal, excess cement, and creation of gaps (29). Alternatives, such as the introduction of hot gutta percha, have shown better adaptation to the canal walls and a greater degree of homogeneity (30). In our case, we believe that both activation of the irrigating solutions and thermoplastic sealing were the keys to success in achieving proper sealing of the apical branches of the lateral incisor.

In the periodontal field, an enamel matrix derivative (Emdogain) has been used for regeneration in recently reported cases (31) and appears to increase the levels of radiographic bone and clinical attachment (32). Recently published studies have shown clinical evidence of tissue regeneration by deposition of cement on the root surface after application of these proteins (33). Treatment with Emdogain is based on imitating the natural events that occur during the development of the root. The root sheath of Hertwig is an apical extension of the enamel organ. During the formation of the root, the root sheath secretes proteins of the enamel matrix, which in turn are involved in the formation of the acellular cementum (34). Thus, it seems that this novel compound based on proteins derived from enamel matrix has the ability to induce promotion of the acellular cementum, which plays an important role in the formation and healing of the periodontal ligament and alveolar bone (35). We justified its use in the case presented here, in which the binding of the periodontal ligament and alveolar bone healing were evident after 1 year of treatment.

Another positive factor in the healing process is the postoperative stability of the wound, achieved through the least possible flap elevation and a stable suture technique. In the early phase of healing, wound integrity is dependent on the stability of the flap

1 and suturing technique (36). The suture material is another influential factor. It has been  
2 shown that monofilament suture materials (such as Goretex) are associated with reduced  
3  
4 accumulation of plaque (37), greater resistance to penetration of fluids, and thus better  
5  
6 healing (38). The time of suture removal after surgery has also been controversial.  
7  
8 Despite this, it is generally advised to remove sutures 2 to 7 days after the intervention  
9  
10 (39). However, other factors are also involved in the healing process, including the  
11  
12 microanatomy of the patient, the microbiota, general health status, oxygenation, and  
13  
14 tissue care.  
15  
16  
17  
18  
19

20           Although the factors involved in the treatment described here are numerous and  
21  
22 varied, the prognosis of a tooth with a palatogingival groove depends mainly on the  
23  
24 severity of the periodontal problem and the extent and accessibility of the groove (31).  
25  
26 The key to successful treatment, therefore, is the ability to adequately treat the  
27  
28 periodontal defect (40). However, a favorable outcome requires a comprehensive  
29  
30 approach to the problem with knowledge and understanding of all of the factors  
31  
32 involved in the disease process.  
33  
34  
35  
36

### 37           **Acknowledgement**

38           "The authors deny any conflicts of interest"  
39  
40  
41  
42  
43  
44  
45  
46  
47  
48  
49  
50  
51  
52  
53  
54  
55  
56  
57  
58  
59  
60  
61  
62  
63  
64  
65

## References

- 1  
2  
3 (1) "Palatogingival Groove: Endodontic- Periodonal Management-  
4 Case Report". Kanika Attam, MDS, Raj Tiwary. JOE 2010; 36;10.  
5  
6
- 7  
8 (2) "Palato-gingival grooves in maxillary incisors. A possible  
9 predisposin factor to localised peridental disease". Lee KW, Lee EC Poon KY. Br  
10 Dent J 1968;124;14-8  
11  
12
- 13 (3) "The distolingual Groove in the maxillary lateral incisor: a  
14 periodontal hazard" Everett FG, Kramer CM. J. Periodontol 1972;43:352-61.  
15  
16
- 17 (4) "The relationship of palato-  
18 gingival grooves to localized periodontal disease." Withers JA, Brunsvold  
19 MA, Killoy WJ, Rahe AJ. J Periodontol. 1981 Jan;52(1):41-4.  
20  
21
- 22 (5) "Complex facial radicular groove in a maxillary lateral incisor."  
23 Goon WW<sup>1</sup>, Carpenter WM, Brace NM, Ahlfeld RJ. J Endod. 1991 May;17(5):244-  
24 8.  
25  
26
- 27 (6) "Macroscopic and microscopic analysis of the palato-  
28 gingival groove." Lara VS<sup>1</sup>, Consolaro A, Bruce RS. J Endod. 2000 Jun;26(6):345-  
29 50.  
30  
31
- 32 (7) "Management of palato radicular Groove in maxillary lateral  
33 incisor" K.V.Kishan, Vani Hegde, K.C. Ponnappa  
34  
35
- 36 (8) Glossary of endodontic terms. American Association of  
37 Endodontists. 7th ed. Chicago, IL, 2003.  
38  
39
- 40 (9) "The prevalence, location and conformation of palato-radicular  
41 grooves in maxillary incisors" Kogon SI. J Periodontol 1986;57;231-4  
42  
43
- 44 (10) "Relationship between palato-radicular grooves and localized  
45 periodontitis" Hou GL, Tsai CC. J Clin Periodontol 1993;20:678-82  
46  
47  
48  
49  
50  
51  
52  
53  
54  
55  
56  
57  
58  
59  
60  
61  
62  
63  
64  
65

1  
2 (11) “ Endodontic Failure attributable to a complex radicular lingual  
3 Groove” Peikoff MD, Perry JB, Chapnick LA. BR Dent J 1968; 124: 14-8

4  
5 (12) “Predictable endodontic and periodontic failures as a result of  
6 radicular anomalies” Simon JH, Glick DH, Frank AL. Oral Surg Oral Med Oral  
7 Pathol 1971;31:823-6  
8  
9

10  
11 (13) “Combined endodontic therapy and periapical surgery with MTA  
12 and bone graft in treating palatogingival groove”. Mittal M<sup>1</sup>, Vashisth P, Arora  
13 R, Dwivedi S. BMJ Case Rep. 2013 Apr 18;2013.  
14  
15  
16

17 (14) “Endodontic Topics.” Ilan Rotstein, James H.Simon. 2006,13,34-  
18 56  
19  
20  
21  
22

23 (15) “Successful treatment of a radicular groove by intentional replanta  
24 tion and Emdogain therapy.” Al-Hezaimi K, Naghshbandi J, Simon JH, Oglesby  
25 S, Rotstein I. Dent Traumatol. 2004 Aug;20(4):226-8.  
26  
27  
28  
29  
30  
31

32 (16) “Endodontic failure attributable to  
33 a complex radicular lingual groove.” Peikoff MD, Perry JB, Chapnick LA. J  
34 Endod. 1985 Dec;11(12):573-7  
35  
36  
37  
38  
39

40 (17) “Scanning electron microscopic investigation of maxillary lateral  
41 incisors with a radicular lingual groove.” Gao ZR<sup>1</sup>, Shi JN, Wang Y, Gu FY. Oral  
42 Surg Oral Med Oral Pathol. 1989 Oct;68(4):462-6.  
43  
44  
45  
46  
47

48 (18) “The relationship of endodontic-periodontic lesions.” Simon  
49 JH<sup>1</sup>, Glick DH, Frank AL. J Endod. 2013 May;39(5):e41-6. doi:  
50 10.1016/j.joen.2013.02.006.  
51  
52  
53  
54

55 (19) “Cone beam computed tomography (CBCT) in endodontics.”  
56 Patel S, Kanagasingam S, Mannocci F. Dent Update. 2010;37(6):373-9.  
57  
58  
59  
60  
61  
62  
63  
64  
65

1  
2  
3  
4  
5  
6  
7  
8  
9  
10  
11  
12  
13  
14  
15  
16  
17  
18  
19  
20  
21  
22  
23  
24  
25  
26  
27  
28  
29  
30  
31  
32  
33  
34  
35  
36  
37  
38  
39  
40  
41  
42  
43  
44  
45  
46  
47  
48  
49  
50  
51  
52  
53  
54  
55  
56  
57  
58  
59  
60  
61  
62  
63  
64  
65

(20) “The application of cone-beam computed tomography in diagnosing the lesions of apical periodontitis of posterior teeth.” Ma L, Zhan FL, Qiu LH, Xue M. Shanghai Kou Qiang Yi Xue. 2012;21(4):442-6.

(21) “Outcome of root canal treatment in dogs determined by periapical radiography and cone-beam computed tomography scans.” Garcia de Paula-Silva FW, Hassan B, Bezerra da Silva LA, Leonardo MR, Wu MK. J Endod. 2009;35(5):723-6.

(22) “A new periapical index based on cone beam computed tomography.” Estrela C, Bueno MR, Azevedo BC, Azevedo JR, Pecora JD. J Endod. 2008;34(11):1325-31

(23) “The use of cone beam computed tomography in the management of dens invaginatus affecting a strategic tooth in a patient affected by hypodontia: a case report.” Durack C, Patel S. Int Endod J. 2011;44(5):474-83

(24) “The radicular palatal groove--a therapeutic modality.” Friedman S, Goultschin J. Endod Dent Traumatol. 1988 Dec;4(6):282-6.

(25) “Endodontic applications of guided tissue regeneration in endodontic surgery.” Rankow HJ<sup>1</sup>, Krasner PR. J Endod. 1996 Jan;22(1):34-43.

(26) “The efficacy of ultrasonic irrigation to remove artificially placed dentine debris from different-sized simulated plastic root canals.” Lee SJ, Wu MK, Wesselink PR. Int Endod J. 2004;37:607-12.

(27) “Review of contemporary irrigant agitation techniques and devices.” Gu LS, Kim JR, Ling J, Choi KK, Pashley DH, Tay FR. J Endod. 2009;35:791-804

1  
2  
3  
4  
5  
6  
7  
8  
9  
10  
11  
12  
13  
14  
15  
16  
17  
18  
19  
20  
21  
22  
23  
24  
25  
26  
27  
28  
29  
30  
31  
32  
33  
34  
35  
36  
37  
38  
39  
40  
41  
42  
43  
44  
45  
46  
47  
48  
49  
50  
51  
52  
53  
54  
55  
56  
57  
58  
59  
60  
61  
62  
63  
64  
65

(28) Endodontics, 5th edn Ingle JE, Backland LK 2002. Hamilton, Ontario, Canada: BC Decker Inc.

(29) “A comparison of the area of the canal space occupied by gutta-percha following four gutta-percha obturation techniques using Procosol sealer.” Eguchi DS, Peters DD, Hollinger JO, Lorton L. J Endod. 1985 Apr;11(4):166-75.

(30) “Filling root canals in three dimensions.” Schilder H. Dent Clin North Am. 1967 Nov;7:23-44.

(31) “Bilateral buccal radicular groove in maxillary incisors: case report.” Kerezoudis NP, Siskos GJ, Tsatsas V. Int Endod J. 2003 Dec;36(12):898-906

(32) “Periodontal regeneration with enamel matrix derivative in one human experimental defect. A case report.” Heijl L<sup>1</sup>. J Clin Periodontol. 1997 Sep;24(9 Pt 2):693-6.

(33) “Successful treatment of a radicular groove by intentional replantation and Emdogain therapy: four years follow-up.” Al-Hezaimi K<sup>1</sup>, Naghshbandi J, Simon JH, Rotstein I. Oral Surg Oral Med Oral Pathol Oral Radiol Endod. 2009 Mar;107(3):e82-5. doi: 10.1016/j.tripleo.2008.11.012. Epub 2009 Jan 25.

(34) “Formation of intermediate cementum. III: 3H-tryptophan and 3H-proline uptake into the epithelial root sheath of Hertwig in vitro.” Lindskog S, Hammarström L. J Craniofac Genet Dev Biol. 1982;2(2):171-7.

1  
2  
3  
4  
5  
6  
7  
8  
9  
10  
11  
12  
13  
14  
15  
16  
17  
18  
19  
20  
21  
22  
23  
24  
25  
26  
27  
28  
29  
30  
31  
32  
33  
34  
35  
36  
37  
38  
39  
40  
41  
42  
43  
44  
45  
46  
47  
48  
49  
50  
51  
52  
53  
54  
55  
56  
57  
58  
59  
60  
61  
62  
63  
64  
65

(35) “Periodontal regeneration in a buccal dehiscence model in monkeys after application of enamel matrix proteins.” Hammarström L<sup>1</sup>, Heijl L, Gestrelus S. *J Clin Periodontol*. 1997 Sep;24(9 Pt 2):669-77.

(36) “Repair following mucoperiosteal flap surgery with full gingival retention.” Hiatt, W. H., Stallard, R. E., Butler, E. D. & Badget, B. (1968) *Journal of Periodontology* 39, 11–16.

(37) “A scanning electron microscope study of plaque accumulation on silk and PVDF suture materials in oral mucosa.” Parirokh M, Asgary S, Eghbal MJ, Stowe S, Kakoei S. *Int Endod J*. 2004;37:776–81.

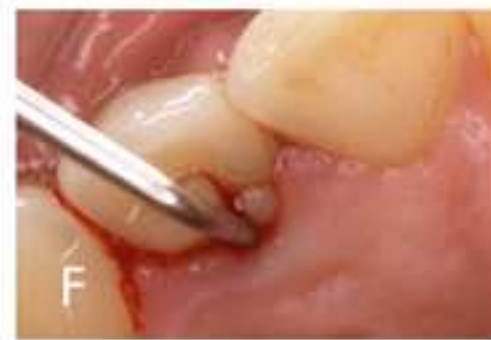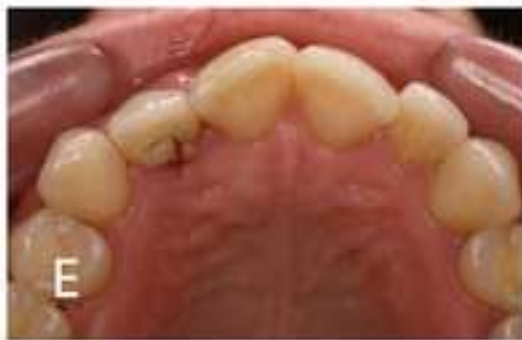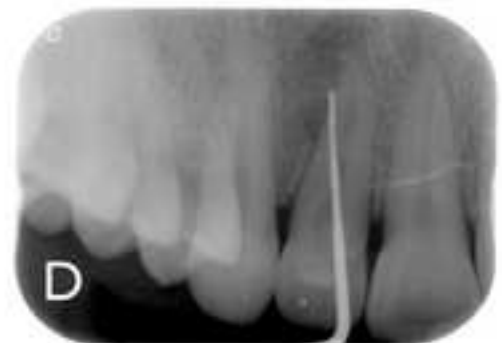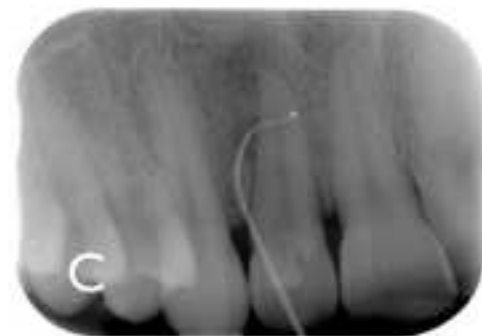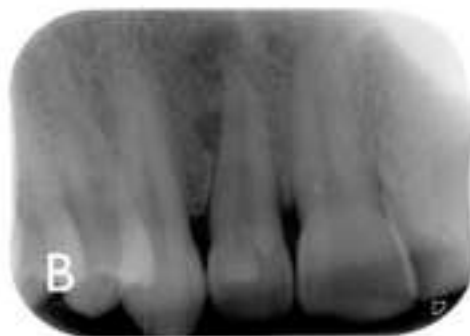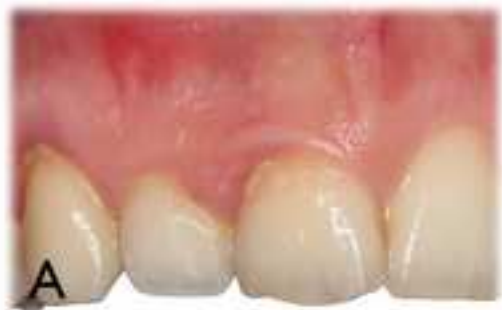(38) Kim S. Endodontic microsurgery. In: Cohen S, Burns RE, editors *Pathways of the Pulp*. 8th Edition. St Louis, MO, USA: Mosby ; 2002. p. 705.

(39) Endodontic surgery. Morrow SG, Rubinstein RA. In: Ingle JI, Bakland L, editors. *Endodontics*. 5th Edition. Ontario, Canada: B.C. Decker; 2002. pp. 669–745.

(40) “Combined endodontic-periodontic treatment of a palatal groove: a case report.” Schwartz SA<sup>1</sup>, Koch MA, Deas DE, Powell CA. *J Endod*. 2006 Jun;32(6):573-8. Epub 2006 Apr 4.

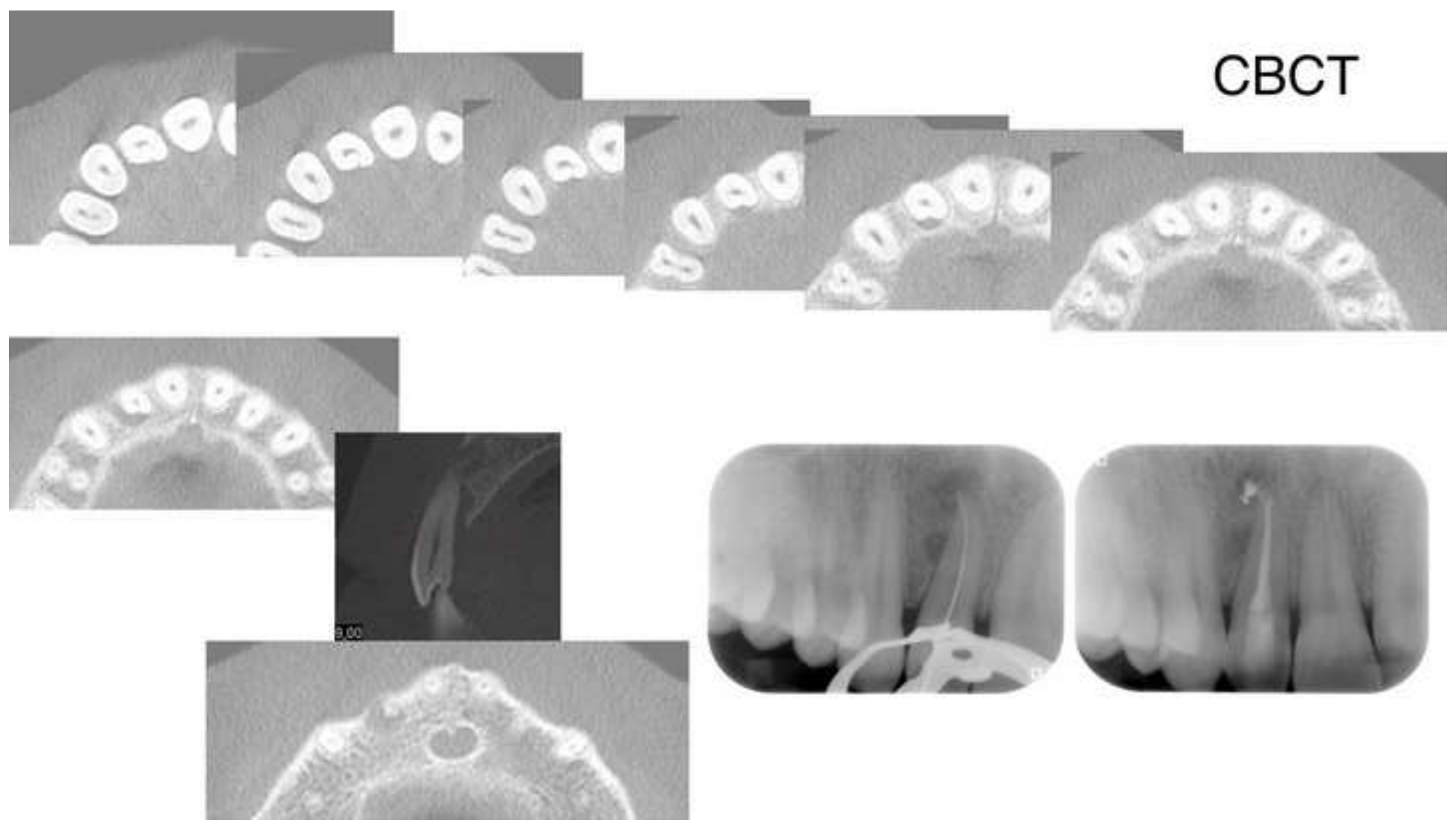
**Figure 1**  
[Click here to download high resolution image](#)

1  
2  
3  
4  
5  
6  
7  
8  
9  
10  
11  
12  
13  
14  
15  
16  
17  
18  
19  
20  
21  
22  
23  
24  
25  
26  
27  
28  
29  
30  
31  
32  
33  
34  
35  
36  
37  
38  
39  
40  
41  
42  
43  
44  
45  
46  
47  
48  
49



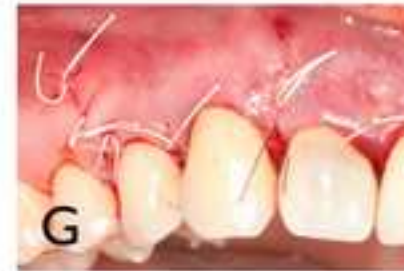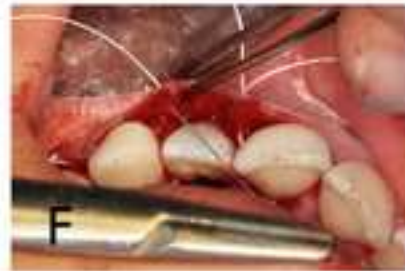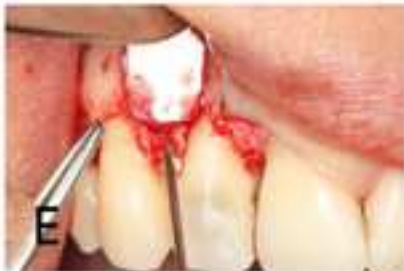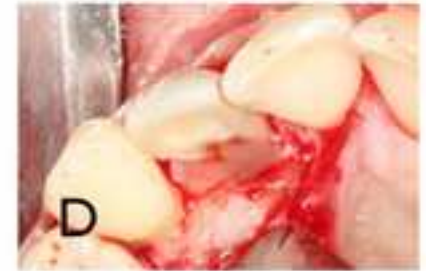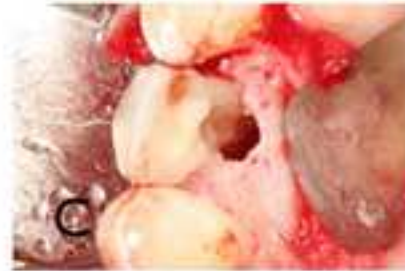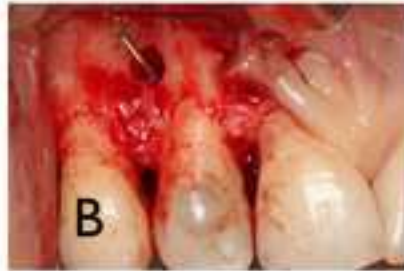
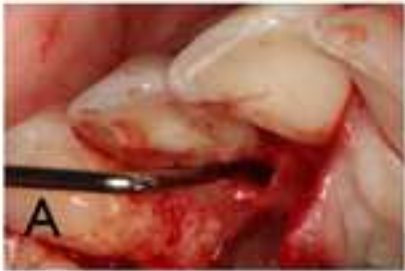**Figure 2**  
[Click here to download high resolution image](#)

1  
2  
3  
4  
5  
6  
7  
8  
9  
10  
11  
12  
13  
14  
15  
16  
17  
18  
19  
20  
21  
22  
23  
24  
25  
26  
27  
28  
29  
30  
31  
32  
33  
34  
35  
36  
37  
38  
39  
40  
41  
42  
43  
44  
45  
46  
47  
48  
49



**Figure 3**  
[Click here to download high resolution image](#)

1  
2  
3  
4  
5  
6  
7  
8  
9  
10  
11  
12  
13  
14  
15  
16  
17  
18  
19  
20  
21  
22  
23  
24  
25  
26  
27  
28  
29  
30  
31  
32  
33  
34  
35  
36  
37  
38  
39  
40  
41  
42  
43  
44  
45  
46  
47  
48  
49



**Figure 4**  
[Click here to download high resolution image](#)

1  
2  
3  
4  
5  
6  
7  
8  
9  
10  
11  
12  
13  
14  
15  
16  
17  
18  
19  
20  
21  
22  
23  
24  
25  
26  
27  
28  
29  
30  
31  
32  
33  
34  
35  
36  
37  
38  
39  
40  
41  
42  
43  
44  
45  
46  
47  
48  
49

