



# Reconstruction of plantar surgical defects with synthetic dermal matrix and split-thickness skin grafts: A case series and functional podiatry outcomes

Pedro Gil-Pallares MD<sup>1,2</sup> | Carlota González-Moure MD<sup>1</sup> |  
 Abián Mosquera-Fernández PhD<sup>3</sup> | Laura Rosende-Maceiras MD<sup>1</sup> |  
 Teresa Usero-Bárcena MD<sup>1</sup> | Sandra Peña-López MD<sup>1</sup> | Olalla Figueroa-Silva PhD<sup>1</sup> |  
 Óscar Suárez-Amor MD<sup>4</sup> | Laura Taboada-Paz MD<sup>1</sup> | Benigno Monteagudo PhD<sup>1</sup> |  
 Cristina de las Heras-Sotos MD<sup>1</sup>

<sup>1</sup>Department of Dermatology, Complejo Hospitalario Universitario de Ferrol, Ferrol, Spain

<sup>2</sup>Universidad de Santiago de Compostela, Santiago, Spain

<sup>3</sup>Department of Health Sciences, Faculty of Nursing and Podiatry, University of A Coruña, A Coruña, Spain

<sup>4</sup>Hospital General Juan Cardona, Ferrol, Spain

## Correspondence

Pedro Gil-Pallares, Department of Dermatology, Complejo Hospitalario Universitario de Ferrol, Ferrol, Spain.  
 Email: [pedro.gil.pallares@rai.usc.es](mailto:pedro.gil.pallares@rai.usc.es)

## Abstract

Reconstruction of surgical defects after wide local excision of acral melanoma on the sole should allow patients to walk and bear weight. Moreover, certain options such as local transposition flaps can compromise follow-up. We present a case series of surgical defects on weight-bearing areas of the sole reconstructed using a synthetic dermal matrix and a split-thickness skin graft. This approach prevents surrounding tissue displacement and results in good functional outcomes assessed by baropodometry and computer-based podoscopy.

## KEYWORDS

acral melanoma, dermal matrix, integra, reconstruction

## INTRODUCTION

Surgical management of plantar acral melanoma can be challenging. In this case series, we present four cases of surgical defects following wide local excision of plantar acral melanoma that were reconstructed using a synthetic dermal matrix and a split-thickness skin graft (STSG) to preserve function.

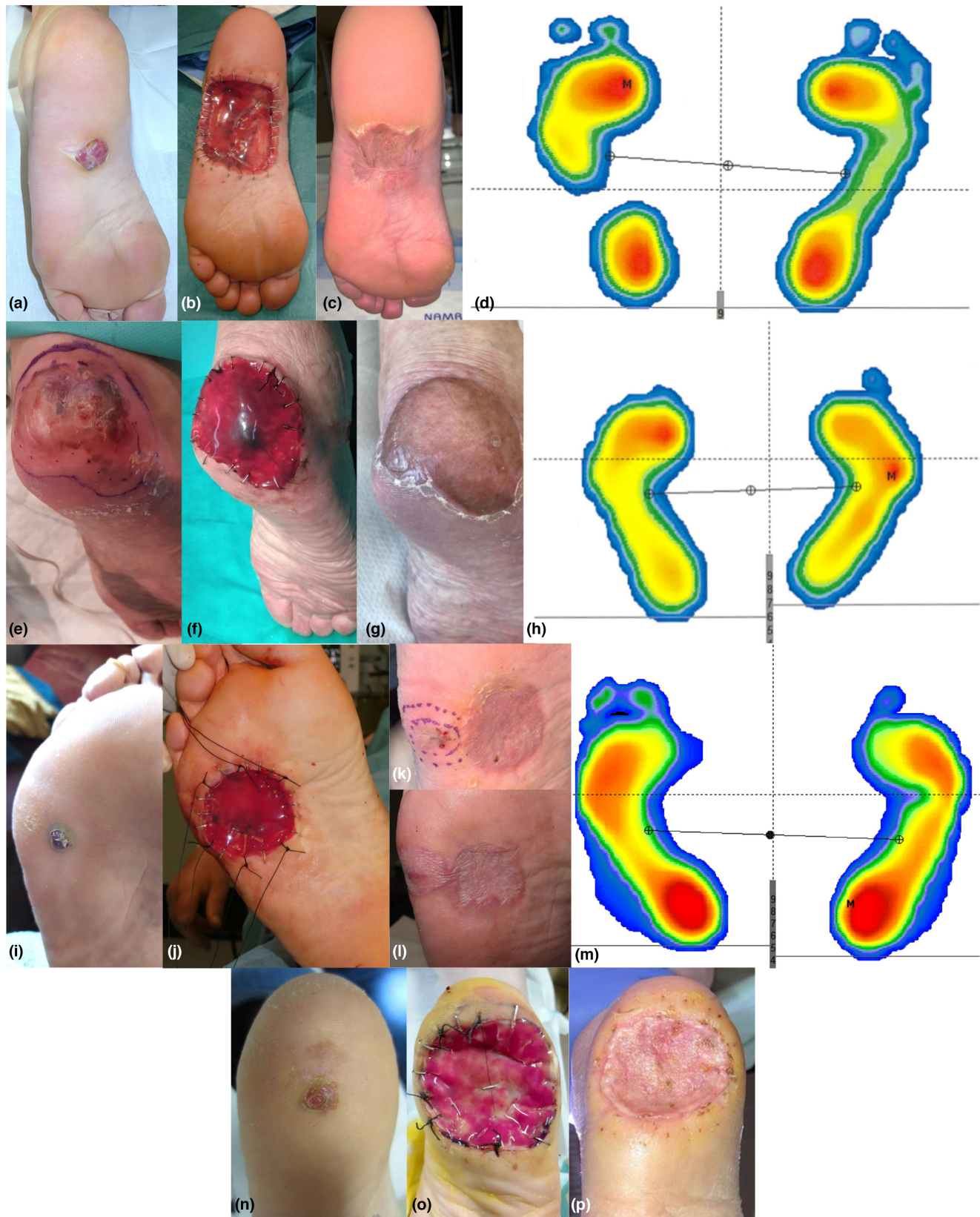
Four patients (three women and one man with a mean age of 72.8 years) underwent wide local excision due to invasive plantar acral melanoma (mean Breslow thickness,

5.85 mm). All the surgical defects were reconstructed using Integra® Bilayer Wound Matrix (IBWM) and a sterile gauze bolster dressing, both sutured to the edge of the wound (Figure 1). The edges of the IBWM were examined weekly for colour changes and signs of early infection in an outpatient setting. Once the colour of the IBWM had progressed to a peach-vanilla colour, which typically takes 3–5 weeks on the sole (Table 1), the bolster and silicone layer of the IBWM were removed and the defects reconstructed with an STSG. A non-adherent bolster dressing was sutured to the STSG and left for 2 weeks. Three

Pedro Gil-Pallares and Carlota González-Moure contributed equally as first authors.

This is an open access article under the terms of the [Creative Commons Attribution-NonCommercial-NoDerivs](https://creativecommons.org/licenses/by-nc-nd/4.0/) License, which permits use and distribution in any medium, provided the original work is properly cited, the use is non-commercial and no modifications or adaptations are made.

© 2023 The Authors. *Australasian Journal of Dermatology* published by John Wiley & Sons Australia, Ltd on behalf of Australasian College of Dermatologists.



months after surgery, a local cutaneous metastasis was detected next to the graft in patient 3 (Figure 1k); this was excised and the defect was reconstructed with a full-thickness skin graft since there was sufficient underlying

tissue (Figure 1l). Footprints and pressure distributions were assessed by static and dynamic baropodometry and computer-based podoscopy in three patients 1–2 years after surgery (Figure 1d,h,m).



**FIGURE 1** Patient 1: (a) 2.5 × 1.8 cm nodular melanoma (Breslow thickness, 12 mm) on the sole. (b) Three weeks after wide local excision and reconstruction with IBWM, just before STSG application. (c) Result after 2 years. (d) Podiatry study with redistribution of loads towards the forefoot. Patient 2: (e) 6 × 4 cm acral lentiginous melanoma (Breslow thickness, 3.9 mm) on the heel. (f) Four weeks after wide local excision and reconstruction with IBWM, before STSG application. (g) Result after 1 year. (h) Light overload on the fifth metatarsal and reduced pressure on the heel. Patient 3: (i) 1 × 1.5 cm nodular melanoma (Breslow thickness, 5 mm) in the lateral metatarsal region of the sole. (j) Five weeks after wide local excision and IBWM placement, before STSG application. (k) Cutaneous metastasis 3 months after surgery (biopsied). (l) Outcome 1 year after excision and reconstruction with full-thickness skin graft. (m) Greater pressure on the heel with no functional changes. Patient 4: (n) 2.8 × 3 cm acral lentiginous melanoma (Breslow thickness, 2.5 mm) on the heel. (o) Five weeks after wide local excision and reconstruction with IBDM, before STSG application. (p) Appearance after 2 months.

**TABLE 1** Patient characteristics, reconstruction details and functional outcomes.

	Case 1	Case 2	Case 3	Case 4
Sex/Age	♀ 62	♀ 90	♂ 70	♀ 69
Localization	Medial plantar arch	Heel	Lateral metatarsal area	Heel
Size	2.5 × 1.8 cm	6 × 4 cm	1 × 1.5 cm	2.8 × 3 cm
Melanoma subtype	Nodular	Acral lentiginous	Nodular	Acral lentiginous
Breslow thickness	12 mm	3.9 mm	5 mm	2.5 mm
Time until STSG	3 weeks	4 weeks	5 weeks	5 weeks
Functional study	Redistribution of loads towards forefoot. Functionality not affected	Reduction of pressure on heel and light overload of the fifth metatarsal. No compromise of functionality	Higher pressure on the heel, with no functional repercussion.	Not performed

The main challenge when reconstructing surgical defects following the excision of acral melanoma on the foot is to preserve function. A range of flaps offering greater thickness and cushioning are frequently used in weight-bearing areas.<sup>1,2</sup> Alternatives include secondary intention healing<sup>3</sup> and skin grafts.<sup>4</sup> Previous studies have suggested that dermal substitutes and STSGs may ease reconstruction by adding extra tissue to soften the impact on weight-bearing areas.<sup>5,6</sup> Such an approach prevents displacement of surrounding skin and does not compromise follow-up or early detection of local recurrence or metastasis, as shown in patient 3.

The aesthetic outcomes in this case series were satisfactory (Figure 1c,g,k,p). Mild asymptomatic compensatory hyperkeratosis was observed in pressure areas but it did not cause discomfort or affect walking. The podiatry tests showed optimal functional outcomes, and the light load distribution modifications observed did not require customized orthotic insoles.

## CONCLUSION

Reconstruction of surgical defects following wide local excision of plantar acral melanoma in weight-bearing areas using IBWM and STSGs resulted in very good functional outcomes assessed by static and dynamic foot pressure analysis. While comparative studies with

other reconstructive techniques are needed, we believe that plantar defect reconstruction with synthetic dermal substitutes and STSGs after wide local excision of acral melanoma is a safe and simple procedure that facilitates follow-up and preserves function.

## CONFLICT OF INTEREST STATEMENT

The authors declare no conflicts of interest.

## CONSENT STATEMENT

All patients signed informed consent for publication of the case details and images.

## ORCID

Pedro Gil-Pallares <https://orcid.org/0000-0001-8469-1942>

Carlota González-Moure <https://orcid.org/0000-0002-3333-6040>

## REFERENCES

- Kim JH, Lee CR, Kwon HJ, Oh DY, Jun YJ, Rhie JW, et al. Two-team-approached free flap reconstruction for plantar malignant melanoma: an observational (STROBE-compliant) trial. *Medicine (Baltimore)*. 2022;101:e29442. <https://doi.org/10.1097/MD.00000000000029442>
- Larrañaga JJ, Picco PI, Yanzon A, Figari M. Reconstruction of hind and mid-foot defects after melanoma resection using the reverse sural flap: a case series. *Surg J*. 2017;3:e124–7. <https://doi.org/10.1055/s-0037-1604473>



3. Jung JY, Roh HJ, Lee SH, Nam K, Chung KY. Comparison of secondary intention healing and full-thickness skin graft after excision of acral lentiginous melanoma on foot. *Dermatol Surg*. 2011;37:1245–51. <https://doi.org/10.1111/j.1524-4725.2011.02043.x>
4. Zyman LM, Cunha JAJ d, Gimenez AO, Maia M. Acral melanoma: considerations about the surgical management of this tumor. *An Bras Dermatol*. 2019;94:632–3. <https://doi.org/10.1016/j.abd.2019.09.019>
5. Zhang X, Sun Y, Hou Z, Luo B, Li C, Jiang K, et al. Application of dermal regenerative template in reconstructing skin defects after plantar malignant melanoma excision. *J BUON*. 2021;26:2141–8.
6. Kang S-W, Park J-K, Shon H-C, Choi ES, Kim DS, Min KT. Skin graft using MatriDerm® for plantar defects after excision of

skin cancer. *Cancer Manag Res*. 2019;11:2947–50. <https://doi.org/10.2147/CMAR.S198568>

**How to cite this article:** Gil-Pallares P, González-Moure C, Mosquera-Fernández A, Rosende-Maceiras L, Usero-Bárcena T, Peña-López S, et al. Reconstruction of plantar surgical defects with synthetic dermal matrix and split-thickness skin grafts: A case series and functional podiatry outcomes. *Australas J Dermatol*. 2023;64:e357–e360. <https://doi.org/10.1111/ajd.14161>