

ORIGINAL ARTICLE OPEN ACCESS

Early Buccal Bone Resorption in Areas With or Without Keratinized Tissue and Different Mucosal Thickness at Implants in Healed Sites: An Experimental Animal Study

Antonio Liñares¹  | Hong Jin Tan^{1,2}  | Fernando Muñoz³  | Dragana Rakasevic^{1,4} | Yago Leira¹  | Juan Blanco¹ 

¹Periodontology Unit, Faculty of Odontology, University of Santiago de Compostela and Medical-Surgical Dentistry Research Group (GI-2117), Health Research Institute of Santiago de Compostela, Santiago de Compostela, Spain | ²Periodontology Unit, Eastman Dental Institute, University College London, London, UK | ³Department of Veterinary Clinical Sciences, University of Santiago de Compostela, iBonelab SL, Lugo, Spain | ⁴Implant and Research Center, School of Dental Medicine, University of Belgrade, Belgrade, Serbia

Correspondence: Antonio Liñares (antonio.linares@usc.es; antonio@antoniolinares.com)

Received: 31 August 2024 | **Revised:** 17 January 2025 | **Accepted:** 2 February 2025

Funding: This work was supported by International Team of Implantology (ITI) grant, grant/award number: 1225_2017.

Keywords: buccal bone resorption | implants | keratinized mucosa | soft tissue thickness

ABSTRACT

Aim: To evaluate early buccal bone resorption (BBR) in areas with or without buccal keratinized tissue (KT), and different mucosal thickness (MT) following implant placement at healed sites.

Materials and Methods: In 9 beagle dogs, three months following the hemimaxilla third and fourth premolars extraction, full-thickness flaps were elevated and two tissue-level implants were inserted. Before suturing, each dog was randomly assigned into 3 groups (control, non-keratinized tissue, NKT and non-keratinized tissue plus connective tissue graft, NKT-CTG). In both experimental groups (NKT and NKT-CTG), buccal KT was excised. In the NKT-CTG group, a CTG was sutured to the buccal alveolar mucosa flap (BF) and coronally repositioned around the implant neck, while in the NKT group, only the BF was repositioned. BF with a 2 mm KT band was repositioned around the implants in the control group. Buccal bone thickness (BBT), MT and KT width were measured clinically at baseline. Three months later, BBR and MT were analysed histologically.

Results: Mucosal thickness at surgery was similar in NKT and control groups (1.33 ± 0.26 mm and 1.67 ± 0.52 mm, respectively). In the NKT-CTG group, MT was 2.50 ± 0.45 . The mean BBT measured at the mid-buccal region was about 1 mm in the 3 groups. Three months later, early BBR was observed in all groups, with mean values of $0.91 \text{ mm} \pm 0.62$ (control), $1.11 \text{ mm} \pm 0.69$ (NKT) and $1.10 \text{ mm} \pm 0.58$ (NKT-CTG). The mean values of MT at a 1.5 mm distance from the marginal mucosa were $1.20 \text{ mm} \pm 0.69$ (control), $2.18 \text{ mm} \pm 0.53$ (NKT) and $3.45 \text{ mm} \pm 1.33$ (NKT-CTG).

Conclusions: Within the limitations of the present investigation, the presence or absence of KT did not affect early BBR. CTG placed in the zones without KT did not prevent early BBR.

Antonio Liñares and Hong Jin Tan contributed equally to the manuscript as first authors.

This is an open access article under the terms of the [Creative Commons Attribution-NonCommercial-NoDerivs](https://creativecommons.org/licenses/by-nc-nd/4.0/) License, which permits use and distribution in any medium, provided the original work is properly cited, the use is non-commercial and no modifications or adaptations are made.

© 2025 The Author(s). *Journal of Clinical Periodontology* published by John Wiley & Sons Ltd.

1 | Introduction

Early buccal bone resorption may occur following implant installation, resulting in a buccal dehiscence defect. Buccal bone resorption (BBR) is defined as the vertical bone loss leading to exposure to the micro-rough surface (Monje et al. 2019). The increasing quality and quantity of hard and soft tissues around and supporting osseous implants, referred to as the 'peri-implant phenotype' (Avila-Ortiz et al. 2020), have been extensively debated, in recent years, especially in light of the rise in the incidence of peri-implant diseases (Derks and Tomasi 2015). The morphologic and dimension features of the peri-implant phenotype, including peri-implant keratinized mucosa width, mucosal thickness, supracrestal tissue height and peri-implant bone thickness may change over time in response to various environmental factors (Avila-Ortiz et al. 2020). Therefore, understanding these changes and their impact on buccal bone is crucial to developing effective prevention strategies.

Keratinized tissue (KT) and mucosal thickness (MT) may play an important role in the functional and aesthetic outcomes of implant therapy, providing stable peri-implant health (Sanz and Heitz-Mayfield 2022). Although adequate keratinized tissue width (KTW) around implants has been extensively studied, its impact on long-term peri-implant health maintenance remains controversial (Berglundh et al. 2018; Wennström and Derks 2012). Recent systematic reviews have shown that insufficient KTW may lead to discomfort during brushing, plaque accumulation, mucosal inflammation, increased probing depth, recession and subsequent marginal bone loss (Ramanauskaite et al. 2022; Thoma et al. 2018). An experimental study in dogs displayed increased buccal bone loss and mucosal recession around implants after three months in the absence of keratinized tissue at the time of implant placement (Bengazi et al. 2014). Thus, the question arises whether KT absence is a risk factor/indicator for peri-implantitis or simply a peri-implantitis consequence. At implants, there is a lack of granulation tissue derived from a periodontal ligament, making it a key factor for keratinization (Liñares et al. 2022). Therefore, disease progression may be different between teeth and implants.

In addition, a minimal mucosal thickness of 2 mm is considered essential for preserving marginal bone (Avila-Ortiz et al. 2020). According to an experimental study (Berglundh and Lindhe 1996), sites with thin peri-implant mucosa (≤ 2 mm) around the implant consistently exhibited bone resorption to facilitate the formation of physiological soft tissue attachment. Consequently, soft tissue augmentation procedures aimed at increasing MT were associated with significantly less marginal bone loss (Thoma et al. 2018). This was confirmed in an experimental study in dogs where less BBR and mucosal recession were obtained by simultaneously placing soft tissue grafts and implants surrounded by thinned alveolar mucosa (Bengazi et al. 2015). However, the effects of KTW and MT on a healed site during implant placement remain unclear.

Despite emerging evidence to support the need for improved peri-implant phenotype, experimental animal studies remain limited in describing how different peri-implant parameters might impact buccal bone changes after implant placement at healed sites. Therefore, the primary objective of this experimental

study was to determine whether the presence or absence of keratinized tissue and mucosal thickness could influence early buccal bone resorption.

2 | Materials and Methods

2.1 | Animals

The study was approved by the regional ethics committee (Ministry of Rural Affairs, Government of Galicia, Lugo, Spain; approval number: 01/18/LU-001). Nine healthy adult female Beagle dogs were used in this experimental study. The average age of the dogs was 3 years old, and they weighed between 12 and 15 kg (Isoquimen, Barcelona, Spain). The maxilla was used as the experimental site. The dogs were housed and monitored daily, with all experimental procedures conducted at the Animal Experimentation Service of the Rof Codina Foundation (Cebiovet, Lugo, Spain) by certified veterinarians.

During the experiment, the dogs were kept in a group within a kennel that had both an indoor area (15 m²) and an outdoor area (20 m²), providing natural light, fresh air and an indoor temperature of 18°C \pm 2°C. The dogs were fed pelleted dog food twice daily with individual bowls, and water was provided continuously. All experimental activities followed Spanish and European Union regulations for the care and use of research animals, adhering to current guidelines for experimental surgical research in implantology and were performed in accordance with the Guidelines for Animal Research: Reporting In Vivo Experiments (ARRIVE) 2.0 (Dard 2012; Kilkenny et al. 2010).

2.2 | Study Design, Sample Size and Allocation

This study was the secondary analysis of a previously published investigation by Liñares et al. (2022), designed as a randomised controlled experimental study. The objectives and data are different from the mentioned published study. No specific power analysis or sample calculation was performed for the present study.

In brief, nine dogs were included in the study and randomly assigned to control and two experimental groups (3 dogs per group) by means of a randomised computer-generated list. The allocation was concealed in sealed envelopes and revealed only after implant placement and prior to suturing.

2.3 | Surgical Procedures and Study Groups

Upon completion of a quarantine period, in each dog, third and fourth premolars (P3 and P4) at randomly selected quadrants of the maxillae were hemisected, carefully elevated and extracted using elevators and forceps, respectively. No bone or soft tissue grafting was performed, leaving the extraction sockets to heal spontaneously. Intravenous cefazolin (20 mg/kg; Kurgan, Normon, Madrid, Spain) and subcutaneous cefovecin (8 mg/kg SID; Convenia, Zoetis, Madrid, Spain) were administered intraoperatively to reduce the risk of infection.

Three months thereafter, surgical procedures were performed. Mid-crestal incisions were made and a full-mucoperiosteal flap was elevated. Two implant osteotomies at sites P3 and P4 were carried out according to the manufacturer's instructions, ensuring that both implants were 10mm apart. Two tissue-level standard implants (3.3mm in diameter and 8mm in length), each with a 2.8mm polished neck, were placed (Straumann AG, Basel, Switzerland), leaving the polished part of the implant supracrestally, and the closure caps were inserted. Prior to suturing, each animal was randomly divided into one of three groups (six implants per group): non-keratinized connective tissue (NKT-CTG), non-keratinized tissue (NKT) and control groups.

In the NKT-CTG group, the KT band was completely removed. Afterwards, the removed KT was de-epithelialized to obtain a connective tissue graft (CTG) which was sutured to the inner buccal alveolar mucosa flap at the coronal level. Both the flap and CTG were coronally repositioned and sutured at the level of the implant

shoulder for transmucosal healing (Figure 1) utilising resorbable sutures (Coated VICRYL RAPIDETM, Ethicon, US LLC).

The NKT group procedures were like the NKT-CTG one, except for not suturing the graft to the buccal alveolar mucosa flap (Figure 2).

In the control group, KT was not removed, therefore the buccal band of at least 2mm of KT was re-positioned and sutured at the level of the implant shoulder using resorbable sutures (Coated VICRYL RAPIDETM, Ethicon, US LLC) (Figure 2).

All groups had non-submerged healing. The healing period was followed by plaque control with chlorhexidine spray for three months (2–3 times per week, Perio-Aid Gel Bioadhesive, Dentaaid, Barcelona). Subsequently, the dogs were sedated and euthanized with an intravenous pentobarbital overdose (40–60 mg/kg; Dolethal, Vetoquinol).

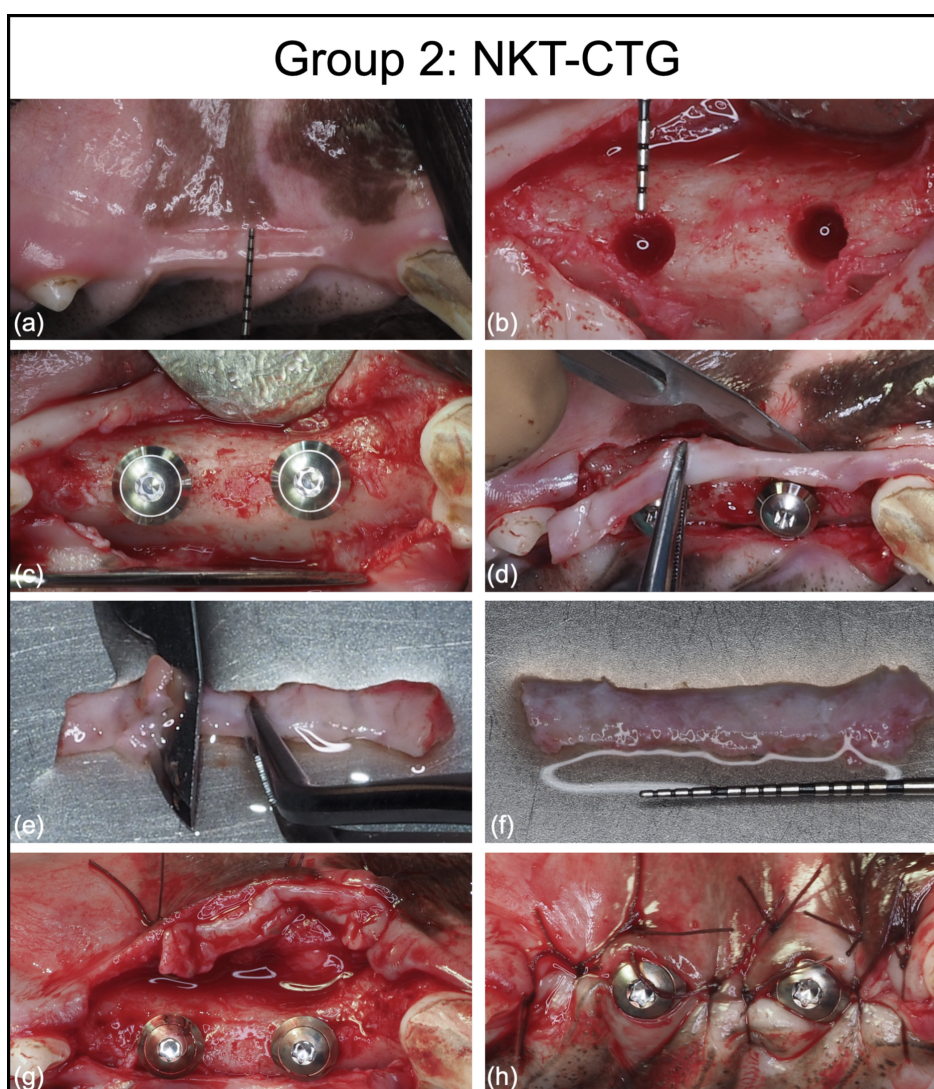


FIGURE 1 | (a–h) Photographs in NKT-CTG group were used to illustrate the surgical procedures performed. (a) Baseline measurement of keratinized tissue width. (b) Full thickness flap elevation and measurement of buccal bone thickness with the use of an UNC-15 probe following implant osteotomy. (c) Implant installation. (d) Complete excision of KT. (e) De-epithelialization of graft. (f) Measurement of graft thickness. (g) Suturing of connective tissue graft to the margin of alveolar mucosa. (h) Final suturing of buccal flap around the implants with primary intention healing. Of note, both NKT and KT groups received the same treatment, but the removal of KT was not performed in KT group. Additionally, both NKT and KT groups did not receive connective tissue graft.

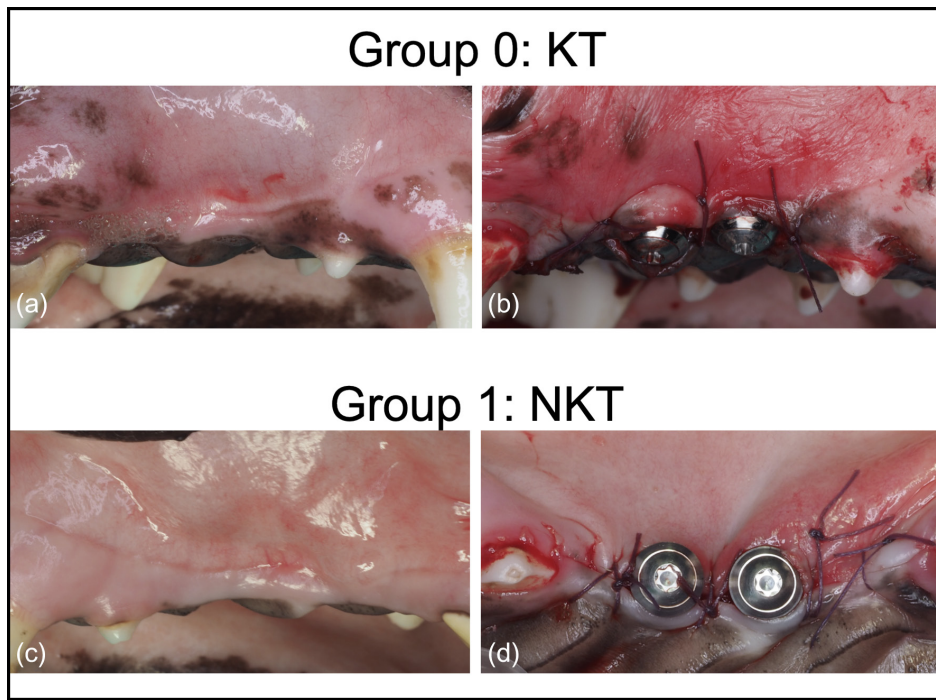


FIGURE 2 | (a–d) Photographs comparing the baseline pre-surgical and post-surgical characteristics of KT and NKT groups. (a) Baseline characteristics of KT group showing a band of KT. (b) Post-surgical characteristics showing a band of KT surrounding the newly installed implants. (c) Baseline characteristics of NKT group showing a band of KT. (d) Post-surgical characteristics showing alveolar mucosa surrounding the newly installed implants.

2.4 | Preparation of Histological Samples and Analyses

The preparation of samples for histological analyses was described in the previously published study (Liñares et al. 2022). A tissue block containing implants and surrounding soft and hard tissues was dissected and processed for ground sectioning according to Donath and Breuner (1982) method. Slides were stained using the Lavai Laczkó technique (Jenö and Géza 1975). Histological and histomorphometric analyses of implants were conducted under a light microscope (BX51; Olympus, Tokyo, Japan).

2.5 | Clinical Measures

All clinical measurements were performed intra-surgically by a calibrated examiner (AL) using a PCP UNC 15 periodontal probe to the nearest 0.5 mm (Hu-Friedy, Chicago, IL). The clinical measurements of buccal bone thickness (BBT) of each osteotomy were measured at the mid-buccal region. Similarly, the CTG thickness and MT were measured with the probe orientated perpendicularly to the CTG and MT. After suturing, the KTW was measured at mid-buccal from the soft tissue margin to mucogingival junction (if present) parallel to the long axis of the implant.

2.6 | Histometric Analysis

The histomorphometric analysis of the peri-implant measurements was performed by a calibrated masked examiner (FM) employing a PC-based image analysis system (CellSens dimensions; Olympus) (Figure 3).

2.6.1 | Buccal Bone Resorption

A vertical measurement was taken parallel to the implant long axis at the following priority identified landmarks:

- IS, Implant shoulder.
- BIC, first bone-to-implant contact.
- IS-BIC, the distance between the implant shoulder and the first bone-to-implant contact.

Considering that the rough-polished border was placed at the level of the buccal bone crest, BBR amount was measured relative to the height of the implants' polished neck, subtracting the 2.8 mm height of the polished neck from the BIC.

2.6.2 | Buccal Mucosal Thickness

Horizontal measurements were taken perpendicular to the implant's long axis at the supracrestal area to assess the thickness of the buccal mucosa. These measurements were made at 0.5, 1, 1.5 and 2 mm apical to the peri-implant mucosal margin (PM). The measured thickness included both the epithelium and the connective tissue.

2.7 | Statistical Analysis

Due to the small sample size, only descriptive analysis was performed. Mean values and standard deviations, median and interquartile range (Q1, Q3) were calculated for the outcome variable IS-B.

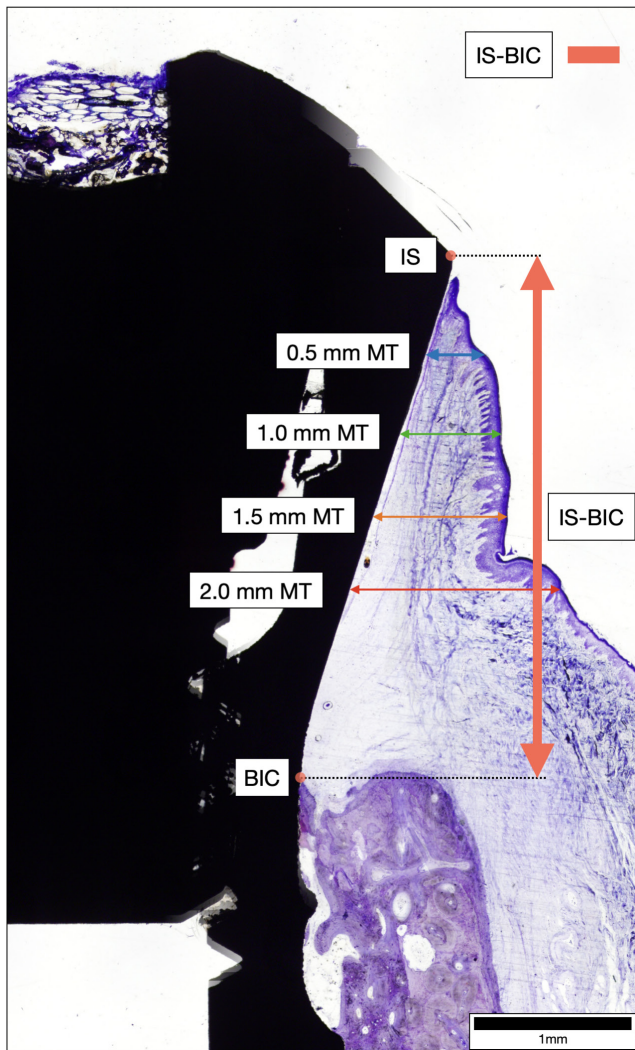


FIGURE 3 | Diagram illustrating the landmarks and measurements for the histomorphometric analysis. Landmarks: IS, implant shoulder; BIC, first bone-to-implant contact. Histological measurements: IS-BIC, distance from implant shoulder to first bone-to-implant contact (red arrow), 0.5 mm MT: Buccal mucosal thickness at 0.5 mm from mucosal margin, 1.0 mm MT: Buccal mucosal thickness at 1.0 mm from mucosal margin, 1.5 mm MT: Buccal mucosal thickness at 1.5 mm from mucosal margin, 2.0 mm MT: Buccal mucosal thickness at 2.0 mm from mucosal margin.

3 | Results

No complication occurred during the healing prior to implant placement. Implants were found to have integrated well. All implants ($n=18$) were included and completed during the follow-up period.

3.1 | Clinical Measurements

Table 1 presents the baseline clinical measurements. Before implant placement, the mean BBT measured at the mid-buccal region was about 1 mm in the three groups: 1.25 ± 0.27 mm in the NKT-CTG group, 1.00 ± 0.00 mm in the control and 0.75 ± 0.27 mm in the NKT group. The NKT-CTG and the NKT groups demonstrated homogeneous MT of 1.33 ± 0.26 mm

following KT removal whereas the control group noted a slightly higher mucosal thickness of 1.67 ± 0.52 mm. Following mucosal grafting with CTG, the NKT-CTG group had an increase in MT of 1.17 mm compared with the NKT group. In the NKT and NKT-CTG groups, keratinized tissue was not detectable as it was completely excised, on the other hand, 2.83 mm of KTW was present in the control group. At 3 months, minimal or no gain in KT was achieved for the NKT and NKT-CTG groups (0.00 mm and 0.4 ± 0.8 mm, respectively), while a decrease of 1.1 ± 0.7 mm in KTW was observed in the control group (Figure 4).

3.2 | Histomorphometric Outcomes

All surgical sites healed uneventfully without complications or osseointegrated implant loss after three months.

3.2.1 | Buccal Bone Resorption

Buccal site sections were used to analyse the buccal bone resorption (BBR) (Figure 5). Histological analyses of the BBR among the groups were presented in Table 2. A total of 18 slides ($n=6$ in control, $n=6$ in NKT, $n=6$ in NKT-CTG) were histologically examined. The BBR was on an average of 1 mm in all groups: 1.11 ± 0.69 mm in NKT, 1.10 ± 0.58 mm in NKT-CTG, while for the control group, it was 0.91 ± 0.62 mm.

3.2.2 | Buccal Mucosal Thickness

The 3 months results of buccal mucosal thickness at different levels from peri-implant marginal mucosa are displayed in Table 2. At 1.5 mm from the mucosal margin, the NKT-CTG group showed a mean MT of 3.45 ± 1.33 mm, the NKT 2.18 ± 0.53 and the control 1.20 ± 0.69 . This means a difference of about 1 mm thickness between the NKT and control group and an extra 1 mm between the NKT-CTG and NKT group. This tendency was also observed at 1- and 2-mm levels (Figure 5).

4 | Discussion

The present study evaluated the impact baseline keratinized tissue (KT) and mucosal thickness (MT) on early buccal bone resorption (BBR) following implant placement at healed sites.

4.1 | Baseline KT

Although no statistical tests were applied for comparison, BBR was found to be similar across the groups, with measurements of 1.10 ± 0.58 mm, 1.11 ± 0.69 mm and 0.91 ± 0.62 mm for NKT-CTG, NKT and control groups, respectively. Buccal bone resorption of approximately 1 mm is consistent with physiological bone resorption reported in other experimental studies. A similar study (Bengazi et al. 2014) also reported a BBR of 0.9 ± 0.6 mm. Furthermore, the same study indicated that early buccal bone loss may be attributed to a lack of KT at implant placement. In the

TABLE 1 | Baseline clinical measurements.

Clinical variables	Group (n = 6)	Mean (SD) (mm)	Median (Q1–Q3) (mm)
BBT	NKT	0.75 ± 0.27	0.75 (0.50–1.00)
	NKT-CTG	1.25 ± 0.27	1.25 (1.00–1.50)
	Control	1.00 ± 0.00	1.00 (1.00–1.00)
MT	NKT	1.33 ± 0.26	1.50 (1.13–1.50)
	NKT-CTG	1.33 ± 0.26	1.50 (1.13–1.50)
	Control	1.67 ± 0.52	2.00 (1.25–2.00)
MT+CTG	NKT	1.33 ± 0.26	1.50 (1.13–1.50)
	NKT-CTG	2.50 ± 0.45	2.50 (2.13–2.88)
	Control	1.67 ± 0.52	2.00 (1.25–2.00)
KTW	NKT	0.00 ± 0.00	0.00 (0.00–0.00)
	NKT-CTG	0.00 ± 0.00	0.00 (0.00–0.00)
	Control	2.83 ± 0.41	3.00 (3.00–3.00)

Note: Data are presented as mean, standard deviation (SD), median and interquartile range (Q1, Q3).

Abbreviations: BBT, buccal bone thickness; KTW, keratinized tissue width; MT, mucosal thickness; MT+CTG, mucosal thickness with connective tissue grafts; NKT, non-keratinized tissue; NKT-CTG, non-keratinized tissue-connective tissue graft.

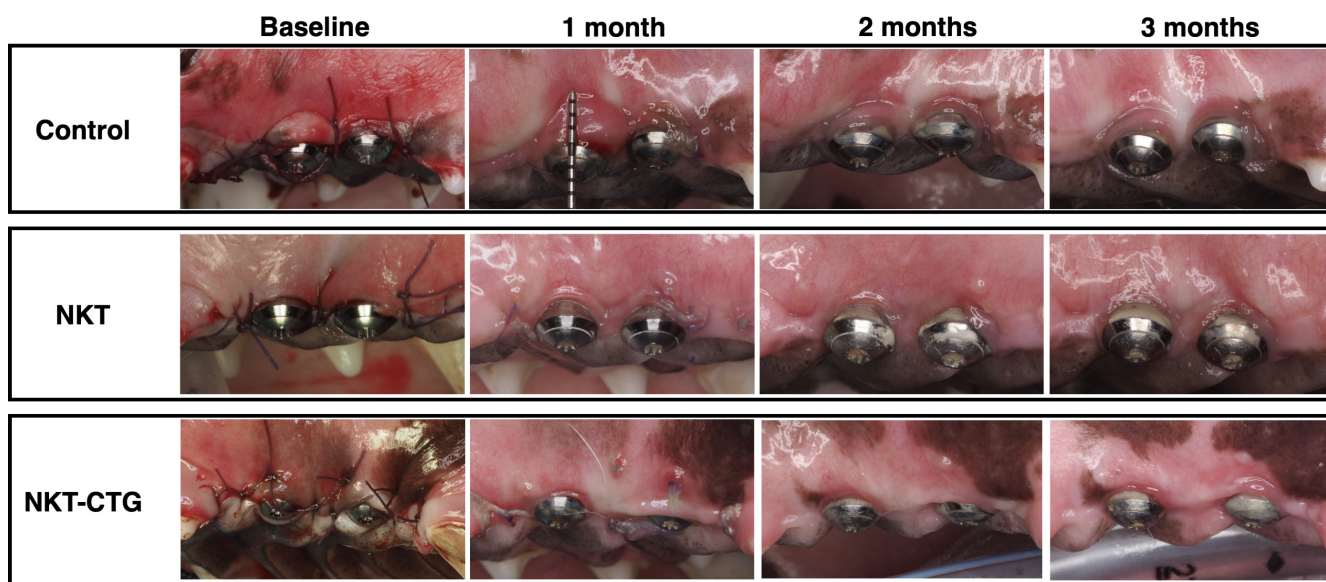


FIGURE 4 | Representative images of the study groups for control, NKT and NKT-CTG at baseline (after suturing) and review at 1, 2 and 3 months on the same animal in each group. Note that no new KT was observed in the NKT group and minimal KT was observed in the NKT-CTG group.

aforementioned study (Bengazi et al. 2014), implants placed in zones lacking KT exhibited a BBR of 1.7 mm, which was 0.8 mm greater than implants surrounded by adequate KT. Contrary to this, in the present study only a 0.19 mm additional bone was lost in the areas without KT compared with the control sites. Implant placement location (jaws) could explain the different outcomes. Compared with the current study, the previous study was conducted in the mandibular arch, where areas without KT were thinner than those with KT. Accordingly, the maxillary alveolar mucosa could be thicker than the mandibular alveolar mucosa.

Conversely, a systematic review in humans reported that reduced KT width is associated with increased marginal bone

loss (Ramanauskaite et al. 2022). However, it is important to note that sites without KT may be associated with early tooth loss, often accompanied by a reduced vestibulum depth (VD). In this regard, VD reduction has been suggested as a contributing factor to early BBR. The KT width of sites with shallow VD was smaller than on sites with adequate VD (1.24 mm vs. 2.38 mm, respectively) according to Halperin-Sternfeld et al. (2016). More recently, a cross-sectional study by Isler et al. (2024) indicated that the absence of KT (odds ratio [OR] = 9.24; 95% CI: 2.73–31.28), and attached mucosa (OR = 19.58; 95% CI: 6.12–62.56), and reduced VD (< 4 mm) (OR = 2.61; 95% CI: 1.05–6.48) were all associated with an increased risk of peri-implantitis. Because reduced VD is often

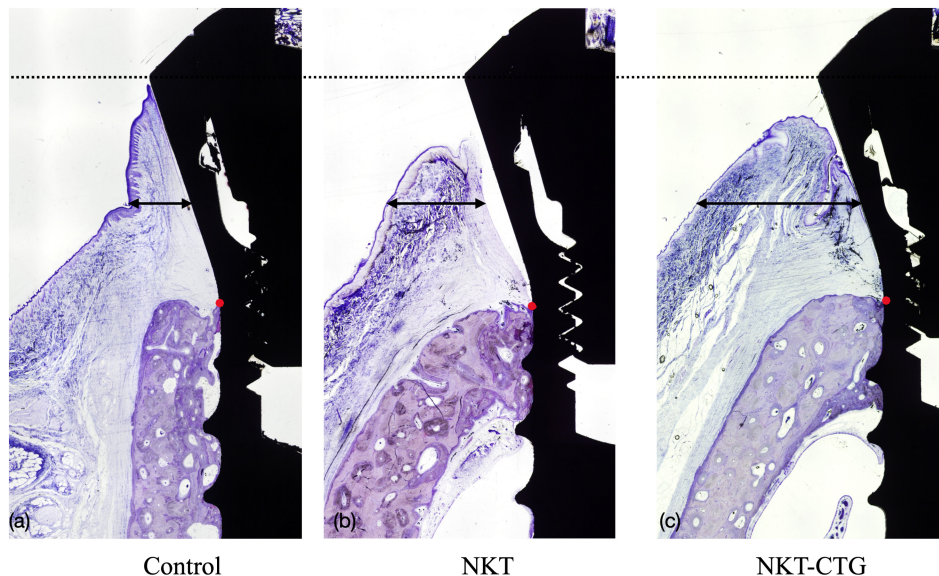


FIGURE 5 | Three months histological buccal sections from (a) the control, (b) NKT and (c) NKT-CTG groups. First bone-to-implant contact (red dots) appears at the same level in the three groups. Black arrows are drawn to highlight the differences in mucosal thickness. Levai-Laczko staining method, original magnification 4 \times .

associated with a lack or decrease in KT, VD might be a significant confounding factor when assessing the KT's contribution to marginal bone levels.

There is an ongoing debate in implant research on whether buccal bone loss and/or peri-implantitis contribute to the lack of KT, or vice versa. In periodontal disease, attachment loss typically occurs in the presence of a band of KT, whereas peri-implantitis is often accompanied by a loss of buccal KT. This distinction may relate to the absence of granulation tissue from the periodontal ligament in implants during disease progression, unlike natural teeth (Liñares et al. 2022). Therefore, while cross-sectional studies often find an association between KT and peri-implantitis, it is important to interpret KT as a consequence of disease progression, rather than a causative factor.

4.2 | Buccal Mucosal Thickness

Mucosal thickness (MT) appears to influence early BBR more than KT alone. According to Bengazi et al. (2014), areas with thin mucosa (1.7 mm) and KT absence displayed greater BBR (0.8 mm) than areas where keratinized mucosa was > 3 mm. The areas without KT had similar MTs to the control group (1.33 ± 0.26 mm vs. 1.67 ± 0.52 mm), explaining the similarities in BBR values between KT and non-KT sites. This resemblance in MT of KT and NKT sites could be related to a thick alveolar mucosa suturing coronally around the implants.

Nevertheless, adding a connective tissue graft (CTG) in the NKT-CTG group did not influence the decrease of early BBR (1.10 ± 0.58 mm, 1.11 ± 0.69 mm and 0.91 ± 0.62 mm for NKT-CTG, NKT and control, respectively). At 3 months, the NKT-CTG group showed about 2 mm thicker buccal mucosa compared with the control, and around 1 mm thicker compared

with the NKT group. This result contrasts with the Bengazi et al. study (2015), where gingival grafting on implants surrounded by alveolar mucosa significantly reduced BBR. A 1.5 mm thick graft was added to the test group to raise MT to 3.2 mm, in order to obtain the MT of the control group (3.1 mm), leading to similar BBR outcomes. While the authors concluded that mucosal grafting could prevent or reduce early BBR in the absence of KT, this conclusion was based on indirect comparisons and the assumption that BBR in the test group was not greater than that of the control.

4.3 | Supracrestal Tissue Height

An adequate supracrestal tissue height (STH) of > 2 mm has been associated with less marginal bone resorption for the establishment of 'biological width' (Linkevicius et al. 2018; Puisys and Linkevicius 2015; Suárez-López Del Amo et al. 2016). In the present study, the buccal flaps in the test groups were coronally positioned and sutured at the implant shoulder, which was 2.8 mm from the bone crest, ensuring a minimum STH of 2.8 mm for all implants. It should also be noted that in contrast to previous studies (Bengazi et al. 2014, 2015), only the buccal KT was removed in this study, while both buccal and lingual KTs were removed in the previous studies. This difference in surgical approach may have influenced the STH and potentially contributed to the differences in BBR observed between the present and earlier studies (1.11 ± 0.69 mm vs. 1.7 ± 0.6 mm, respectively).

4.4 | Buccal Bone Thickness

The ideal buccal bone thickness (BBT) during implant placement has been suggested to be at least 1.5–2 mm in healed sites so as to reduce the risk of biological and aesthetic complications

TABLE 2 | Histomorphometric measurement of buccal bone resorption (BBR) and buccal mucosal thickness (BMT) at 0.5, 1.0, 1.5 and 2.0 mm from mucosal margin at 3 months.

Group	BBR		BMT 0.5 mm		BMT 1.0 mm		BMT 1.5 mm		BMT 2.0 mm	
	Mean (SD) (mm)	Median (Q1-Q3) (mm)	Mean (SD) (mm)	Median (Q1-Q3) (mm)	Mean (SD) (mm)	Median (Q1-Q3) (mm)	Mean (SD) (mm)	Median (Q1-Q3) (mm)	Mean (SD) (mm)	Median (Q1-Q3) (mm)
NKT	1.11 ± 0.69	1.13 (0.73-1.59)	1.78 ± 0.90	1.54 (1.24-2.36)	2.18 ± 1.34	1.84 (1.55-2.39)	2.18 ± 0.53	2.39 (1.86-2.48)	2.60 ± 0.69	2.63 (2.26-0.2.97)
NKT-CTG	1.10 ± 0.58	0.92 (0.73-1.60)	2.08 ± 0.73	1.96 (1.58-2.35)	2.85 ± 1.08	2.60 (2.09-3.71)	3.45 ± 1.33	3.05 (2.75-4.56)	3.94 ± 1.39	3.29 (3.22-5.35)
Control	0.91 ± 0.62	0.75 (0.52-1.25)	0.33 ± 0.16	0.32 (0.24-0.45)	0.76 ± 0.29	0.75 (0.64-0.83)	1.20 ± 0.69	0.97 (0.82-1.72)	1.89 ± 0.71	1.67 (1.37-2.09)

Note: Data are presented as mean, standard deviation (SD), median and interquartile range (Q1, Q3). Abbreviations: BBR, buccal bone resorption; NKT, non-keratinized tissue; NKT-CTG, non-keratinized tissue-connective tissue graft.

(Jensen et al. 2023; Monje et al. 2019). According to Monje et al. (2019), a critical buccal bone thickness of at least 1.5 mm was beneficial in reducing early buccal bone loss. However, in the present study, all groups had mean buccal bone thickness values below 1.5 mm, with only three implants in the NKT-CTG group exceeding 1.5 mm in BBT. This may explain the observed BBR of approximately 1 mm across all groups. A similar BBR was demonstrated in the study by Bengazi et al. (2014) (0.9 mm). Interestingly, implants with a BBT of 2.3 mm placed in molar regions displayed the same BBR as implants with a BBT of 0.9 mm. Consequently, thin alveolar mucosa surrounding implants at initial implant placement may lead to higher BBR, regardless of the thickness of the buccal bony crest.

Some limitations of the present study should be acknowledged. Data from a previously published investigation with a different primary objective was analysed in this study. Therefore, sample size calculations were not performed, and comparative statistical analysis was not possible due to the small sample size. It should be noted, however, that similar sample sizes have been used in previous studies (Bengazi et al. 2014, 2015; Monje et al. 2019), suggesting that the results should be interpreted with caution. Ethical considerations also necessitate reducing the number of animals as much as possible. In addition, conventional periodontal probes were used for intra-surgical measurements, which may not provide the level of precision needed to detect differences of ≤ 0.5 mm. Nonetheless, these measurements are commonly used in clinical practice and were consistent with the methodology of prior studies (Bengazi et al. 2015), allowing for direct comparison.

5 | Conclusions

Within the limitations of this study, it can be concluded that, following implant placement at healed sites:

1. Early buccal bone resorption (BBR ≈ 1 mm) occurred independently of the presence or absence of KT;
2. Additionally, the use of a CTG to increase MT in zones without KT did not prevent BBR.

Author Contributions

Antonio Liñares was responsible for conception, protocol design, grant acquisition, surgeries, histomorphometric analysis, data collection and interpretation, and manuscript drafting. Hong Jin Tan contributed to histomorphometric analysis, data collection and interpretation, and manuscript drafting. Fernando Muñoz was involved in surgeries, animal care, histomorphometric analysis, and data collection. Dragana Rakasevic assisted with drafting and critically revising the manuscript. Yago Leira contributed to data interpretation. Juan Blanco was responsible for conception, protocol design, surgeries, grant acquisition, planning, supervision and manuscript drafting. All authors gave their final approval and agreed to be held accountable for all aspects of the work.

Acknowledgements

The authors would like to express gratitude to Dr. Carlota Blanco, Dr. Paula Ruiz, Dr. Ana Castellanos and Dr. Lucia Maceiras for their assistance during the surgeries and data collection. The authors would also like to thank the staff of the Rof Codina Institute, for managing and caring for the animals. The authors Hong Jin Tan and Dragana Rakasevic

were ITI Scholars in 2024 and 2023, respectively, in the Periodontology Unit, Faculty of Odontology, University of Santiago de Compostela. This work is part of that scholarship.

Ethics Statement

Ministry of Rural Affairs, Government of Galicia, Lugo, Spain; approval number: 01/18/LU-001.

Conflicts of Interest

The authors declare no conflicts of interest.

Data Availability Statement

The data that support the findings of this study are available from the corresponding author upon reasonable request.

References

Avila-Ortiz, G., O. Gonzalez-Martin, E. Couso-Queiruga, and H.-L. Wang. 2020. "The Peri-Implant Phenotype." *Journal of Periodontology* 91, no. 3: 283–288. <https://doi.org/10.1002/JPER.19-0566>.

Bengazi, F., D. Botticelli, V. Favero, A. Perini, J. Urbizo Velez, and N. P. Lang. 2014. "Influence of Presence or Absence of Keratinized Mucosa on the Alveolar Bony Crest Level as It Relates to Different Buccal Marginal Bone Thicknesses. An Experimental Study in Dogs." *Clinical Oral Implants Research* 25, no. 9: 1065–1071. <https://doi.org/10.1111/clr.12233>.

Bengazi, F., N. P. Lang, M. Caroprese, J. Urbizo Velez, V. Favero, and D. Botticelli. 2015. "Dimensional Changes in Soft Tissues Around Dental Implants Following Free Gingival Grafting: An Experimental Study in Dogs." *Clinical Oral Implants Research* 26, no. 2: 176–182. <https://doi.org/10.1111/clr.12280>.

Berglundh, T., G. Armitage, M. G. Araujo, et al. 2018. "Peri-Implant Diseases and Conditions: Consensus Report of Workgroup 4 of the 2017 World Workshop on the Classification of Periodontal and Peri-Implant Diseases and Conditions." *Journal of Clinical Periodontology* 45, no. 20: 286–291. <https://doi.org/10.1111/jcpe.12957>.

Berglundh, T., and J. Lindhe. 1996. "Dimension of the Periimplant Mucosa. Biological Width Revisited." *Journal of Clinical Periodontology* 23, no. 10: 971–973. <https://doi.org/10.1111/j.1600-051x.1996.tb00520.x>.

Dard, M. 2012. "Methods and Interpretation of Performance Studies for Dental Implants." In *Biocompatibility and Performance of Medical Devices*, edited by J. P. Boutrand, 308–344. Woodhead Publishing Ltd.

Derks, J., and C. Tomasi. 2015. "Peri-Implant Health and Disease. A Systematic Review of Current Epidemiology." *Journal of Clinical Periodontology* 42, no. 16: S158–S171. <https://doi.org/10.1111/jcpe.12334>.

Donath, K., and G. Breuner. 1982. "A Method for the Study of Undecalcified Bones and Teeth With Attached Soft Tissues." *Journal of Oral Pathology & Medicine* 11, no. 4: 318–326. <https://doi.org/10.1111/j.1600-0714.1982.tb00172.x>.

Halperin-Sternfeld, M., H. Zigdon-Giladi, and E. E. Machtei. 2016. "The Association Between Shallow Vestibular Depth and Peri-Implant Parameters: A Retrospective 6 Years Longitudinal Study." *Journal of Clinical Periodontology* 43, no. 3: 305–310. <https://doi.org/10.1111/jcpe.12504>.

Isler, S. C., M. Romandini, G. Akca, et al. 2024. "Soft-Tissue Phenotype as a Risk Indicator of Peri-Implantitis and Peri-Implant Soft-Tissue Dehiscence-A Cross-Sectional Study." *Journal of Clinical Periodontology* 51, no. 11: 1443–1457. <https://doi.org/10.1111/jcpe.14059>.

Jenö, L., and L. Géza. 1975. "A Simple Differential Staining Method for Semi-Thin Sections of Ossifying Cartilage and Bone Tissues Embedded in Epoxy Resin." *Mikroskopie* 31, no. 1–2: 1–4.

Jensen, S. S., T. Aghaloo, R. E. Jung, et al. 2023. "Group 1 ITI Consensus Report: The Role of Bone Dimensions and Soft Tissue Augmentation Procedures on the Stability of Clinical, Radiographic, and Patient-Reported Outcomes of Implant Treatment." *Clinical Oral Implants Research* 34, no. S26: 43–49. <https://doi.org/10.1111/clr.14154>.

Kilkenny, C., W. Browne, I. C. Cuthill, M. Emerson, and D. G. Altman. 2010. "Animal Research: Reporting In Vivo Experiments: The ARRIVE Guidelines." *British Journal of Pharmacology* 160, no. 7: 1577–1579. <https://doi.org/10.1111/j.1476-5381.2010.00872.x>.

Liñares, A., A. Rubinos, A. Puñal, F. Muñoz, and J. Blanco. 2022. "Regeneration of Keratinized Tissue Around Teeth and Implants Following Coronal Repositioning of Alveolar Mucosa With and Without a Connective Tissue Graft: An Experimental Study in Dogs: Fifty Years After Karring's Landmark Study: Fifty Years After Karring's 71 Landmark Study." *Journal of Clinical Periodontology* 49, no. 11: 1133–1144. <https://doi.org/10.1111/jcpe.13673>.

Linkevicius, T., R. Linkevicius, J. Alkimavicius, L. Linkeviciene, P. Andrijauskas, and A. Puisys. 2018. "Influence of Titanium Base, Lithium Disilicate Restoration and Vertical Soft Tissue Thickness on Bone Stability Around Triangular-Shaped Implants: A Prospective Clinical Trial." *Clinical Oral Implants Research* 29, no. 7: 716–724. <https://doi.org/10.1111/clr.13263>.

Monje, A., V. Chappuis, F. Monje, et al. 2019. "The Critical Peri-Implant Buccal Bone Wall Thickness Revisited: An Experimental Study in the Beagle Dog." *International Journal of Oral & Maxillofacial Implants* 34, no. 6: 1328–1336. <https://doi.org/10.11607/jomi.7657>.

Puisys, A., and T. Linkevicius. 2015. "The Influence of Mucosal Tissue Thickening on Crestal Bone Stability Around Bone-Level Implants. A Prospective Controlled Clinical Trial." *Clinical Oral Implants Research* 26, no. 2: 123–129. <https://doi.org/10.1111/clr.12301>.

Ramanauskaitė, A., F. Schwarz, and R. Sader. 2022. "Influence of Width of Keratinized Tissue on the Prevalence of Peri-Implant Diseases: A Systematic Review and Meta-Analysis." *Clinical Oral Implants Research* 33, no. 23: 8–31. <https://doi.org/10.1111/clr.13766>.

Sanz, M., and L. Heitz-Mayfield. 2022. "Consensus Report of DGI/SEPA/Osteology Workshop." *Clinical Oral Implants Research* 33, no. 23: 3–7. <https://doi.org/10.1111/clr.13950>.

Suárez-López Del Amo, F., G. H. Lin, A. Monje, P. Galindo-Moreno, and H. L. Wang. 2016. "Influence of Soft Tissue Thickness on Peri-Implant Marginal Bone Loss: A Systematic Review and Meta-Analysis." *Journal of Periodontology* 87, no. 6: 690–699. <https://doi.org/10.1902/jop.2016.150571>.

Thoma, D. S., N. Naenni, E. Figuero, et al. 2018. "Effects of Soft Tissue Augmentation Procedures on Peri-Implant Health or Disease: A Systematic Review and Meta-Analysis." *Clinical Oral Implants Research* 29, no. 15: 32–49. <https://doi.org/10.1111/clr.13114>.

Wennström, J. L., and J. Derks. 2012. "Is There a Need for Keratinized Mucosa Around Implants to Maintain Health and Tissue Stability?" *Clinical Oral Implants Research* 23, no. 6: 136–146. <https://doi.org/10.1111/j.1600-0501.2012.02540.x>.