

Case report

Veillonella atypica bacteraemia: Case report and literature review

Miguel Franco Álvarez ^{a,*}, Andrea Jardi Cuadrado ^b, Mariño Francisco Fernández Cambeiro ^a, Adrián Domínguez Lago ^c, José Antonio Díaz Peromingo ^{a,d}

^a Department of Internal Medicine, Hospital Clínico Universitario de Santiago, Spain

^b Department of Digestive Diseases, Hospital Clínico Universitario de Santiago, Spain

^c Department of Microbiology, Hospital Clínico Universitario de Santiago, Spain

^d University of Santiago de Compostela, Spain

ARTICLE INFO

Keywords:

Veillonella atypica
bacteremia
cirrhosis
enterovesical fistula

ABSTRACT

Veillonella atypica is an anaerobic Gram-negative coccus, a common commensal of the human oral, vaginal and intestinal microbiota, which rarely causes infections in the human host. To date, only two cases of bacteraemia caused by this germ have been reported in the literature. We present the case of a 50-year-old male patient with liver cirrhosis who developed *V. atypica* bacteraemia in the context of acute diverticulitis complicated by an enterovesical fistula.

Introduction

Veillonella atypica is an anaerobic bacterium belonging to the genus *Veillonella*, family *Veillonellaceae*, currently comprising about 20 species, and is found as a commensal, in human oral, vaginal and intestinal mucosa [1]. It is identified as a Gram-negative, non-sporulating coccus characterised by its ability to ferment lactic acid and inability to use carbohydrates or amino acids as an energy source, so it often establishes commensalism with other bacteria such as *Streptococcus* spp. that generates lactate as a product of their metabolism [2,3].

Eight species predominate in the oral cavity (*V. parvula*, *V. dispar*, *V. atypica*, *V. rogosae*, *V. infantium*, *V. denticariosi*, *V. nakazawae* and *V. tobetsuensis*), being abundant in saliva and creating coaggregates with other oral bacteria forming part of the dental plaque, while others are found in genital areas (*V. seminalis* and *V. montpellierensis*) [4].

Infection due to some species has rarely been reported, while others of the genus such as *V. parvula* or *V. dispar* have been more frequently described as pathogens [5,6]. In addition, most of infections in which they are implicated are polymicrobial, being isolated together with other aerobic and anaerobic microorganisms [4]. Cases of endocarditis [6], meningitis [7] or osteomyelitis [5] caused by species of the genus *Veillonella* have been reported.

Even less frequent is the isolation of such species in blood cultures and few publications report bacteraemias caused by *Veillonella* species.

Regarding antimicrobial susceptibility, some studies report resistance rates in *Veillonella* of 59 % to penicillin and 7 % to clindamycin [8]

or 29 % to penicillins and 12 % to clindamycin [9], although in many cases the antibiogram is not reported.

Regarding bacteraemia caused by *V. atypica*, to the best of our knowledge, only two cases have been reported in the medical literature. We present and discuss the case of a 50-year-old cirrhotic male who developed sepsis with *V. atypica* bacteraemia in the context of acute diverticulitis and was subsequently diagnosed with an enterovesical fistula.

Case report

A 50-year-old man with a history of untreated type-2 diabetes mellitus (DM2) and alcoholic liver cirrhosis Child Pugh A6 with clinically significant portal hypertension in the form of small esophageal varices and gastropathy due to portal hypertension (for which he takes propranolol 10 mg every 12 h), consulted to the emergency department for onset of fever with shivering and vomiting, with no other accompanying symptoms. He was previously admitted to hospital on two occasions in the last year with a diagnosis of urinary sepsis with isolation of *E. coli* in blood cultures. Initially, blood pressure was 85/54 mmHg with a heart rate of 85 bpm and normal body temperature. Laboratory tests showed anaemia (Hb 11 g/dL; N: 13.5 – 17.5), low platelet count (50.000/mm³; N: 135.000 – 369.000), elevated C-reactive protein (2.14 mg/dL; N: 0.0 – 0.33) and procalcitonin (11.35 ng/mL; N: <0,05 ng/mL), with normal renal function and liver biochemistry. Table 1 shows the evolution of the main analytical parameters during admission. An abdominal ultrasound

* Correspondence to: Rúa da Choupana s/n, 15706

E-mail address: miguel.franco.alvarez@sergas.es (M. Franco Álvarez).

<https://doi.org/10.1016/j.idcr.2025.e02194>

Received 30 January 2025; Received in revised form 2 March 2025; Accepted 2 March 2025

Available online 4 March 2025

2214-2509/© 2025 The Authors. Published by Elsevier Ltd. This is an open access article under the CC BY-NC-ND license (<http://creativecommons.org/licenses/by-nc-nd/4.0/>).

Table 1
Evolution of the analytical parameters throughout the hospital admission.

Parameter	Day 1	Day 2	Day 3	Day 5	Day 8	Day 10
Leukocytes (x10 ³ /μL)	9.29	5.53	5.62	4.45	4.94	6.42
Neutrophils (%)	89.1	92.0	67.8	65.6	63.8	70.8
Lymphocytes (%)	4.4	3.5	18.0	21.4	23.4	20.7
Hemoglobin (g/dL)	11.5	11.0	9.9	11.5	10.1	11.2
Platelets (x10 ³ /μL)	73.0	50.0	43.0	66.0	74.0	93.0
Creatinine (mg/dL)	1.3	1.34	1.42	01.01	0.88	0.85
Urea (mg/dL)	55.0	59.0	65.0	50.0	39.0	34.0
Total bilirubin (mg/dL)	1.8	1.4	1.1	1.6	1.6	1.7
AST (UI/L)	26.0	22.0	19.0	25.0	22.0	23.0
ALT (UI/L)	29.0	17.0	18.0	22.0	17.0	16.0
Alkaline phosphatase (IU/L)	62.0	45.0	32.0	56.0	60.0	66.0
GGT (UI/L)	74.0	46.0	45.0	87.0	83.0	75.0
C-Reactive Protein (mg/dL)	2.14	2.454	5.662	3.631	1.239	922
Procalcitonin (ng/mL)	11.35	37.72	N/A	N/A	1.88	0.64

exam showed a liver with irregular margins with a ground glass pattern and homogeneous splenomegaly, both of which were attributed to chronic liver disease. Blood and urine cultures were taken and empirical therapy with piperacillin/tazobactam was started. Urine culture was negative. After 36 h, blood culture was positive. Microscopic observation revealed the presence of coccoid forms compatible with Gram-negative cocci. This finding was subsequently confirmed by isolation of colonies on appropriate culture media

(Schaefer agar, 37°C) incubated in an anaerobic atmosphere, identified by MALDI-TOF mass spectrometry (Bruker Daltonics, Germany) as *Veillonella atypica* with a score of 2.33. The sensitivity study was performed with the epsilon test (E-test) methodology using Brucella agar (Becton Dickinson, Germany). Inhibition halos were read after incubation at 37°C in an anaerobic atmosphere for 24 h. The CLSI guideline 2023 was used to interpret the Minimum Inhibitory Concentration (MIC) values of this anaerobic microorganism as sensitive or resistant (Table 2). Once the antibiogram was informed (Table 2), antibiotic therapy was changed to amoxicillin/clavulanic acid. The abdominopelvic CT scan requested during admission revealed a focal parietal thickening of the sigma of 4.3 cm in length, suggestive of a neoplastic lesion, possibly forming an abscess, and a 20 mm hydro-aerial collection was observed between the underside of the lesion and the wall of the bladder dome, which was thickened (Image 1). Consequently, a colonoscopy was performed to clarify the nature of the lesion, detecting a stricture in the sigma, approximately 30 cm from the anal margin, with a non-neoplastic appearance. Biopsies taken from the area showed no data suggestive of malignancy (Colon mucosa is observed without evidence of malignancy or epithelial dysplasia. The only histopathological alteration identified is mild fibrosis of the lamina propria.). The study was also completed with cystoscopy, which described a lesion of about 2–3 cm in the right dome with a solid mamelon-like appearance with inflammatory bullae, which on subsequent histological analysis revealed only oedema and mixed infiltration with lymphoid aggregates of the mucosa. Fifteen days of antibiotic therapy were completed. In light of the emergence of new episodes of urinary tract infection, accompanied by the development of pneumaturia, a new CT scan was performed describing findings suggestive of enterovesical fistula (a reduction in the thickening of the sigmoid wall was described,

Table 2
Antibiogram results.

ANTIBIOTIC	SENSITIVITY	MIC
Penicillin	S	0.5
Amoxicillin-Clavulanic acid	S	0.19
Piperacillin-Tazobactam	S	4
Clindamycin	S	0.094
Metronidazole	S	2

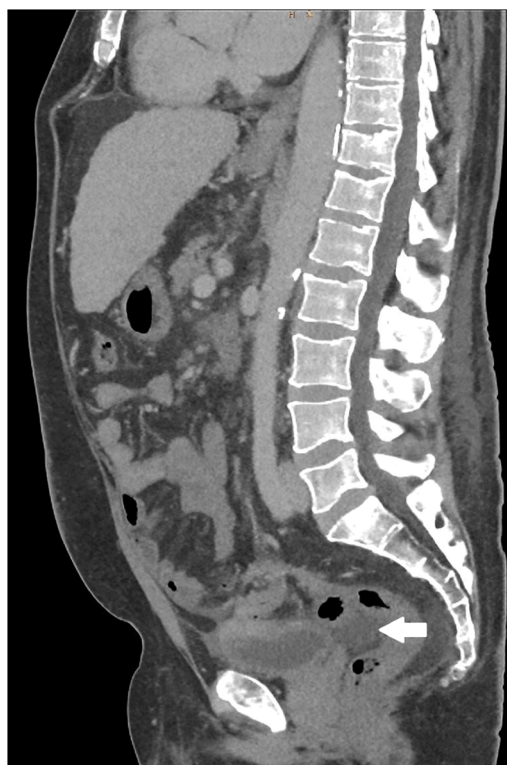


Image 1. The sagittal section of abdominopelvic CT scan showing hydro-aerial collection located between sigma and bladder (white arrow).

probably related to subacute diverticulitis, with a short fistulous tract to the bladder dome and a long sinus tract towards the left wall of the rectosigmoid junction). Cystoscopy was repeated to confirm these findings. In the bladder dome a cleft suggestive of a fistula opening was identified. The patient is currently awaiting surgical repair by sigmoidectomy and raffia of the bladder dome.

Discussion

Following a systematic search in Pubmed, Embase, Scopus and Google Scholar with the terms '*Veillonella atypica*' and 'bacteraemia', only two publications report two cases of bacteraemia caused by this germ in the entire scientific literature [10,11]. The characteristics of both are summarized in Table 3. There are other publications recording cases of bacteraemia caused by this species that do not provide clinical data [12,13].

Like other species in the family, *V. atypica* is considered a common commensal of the microbiota of different mucosa and is rarely a pathogen responsible for infection even in immunocompromised hosts, with only two cases of severe infections due to this germ in the form of retropharyngeal abscess and pneumonia respectively [14,15]. The clinical characteristics of these cases are summarized in Table 4.

Our patient presented a bacteremic infection, most likely due to the existence of an acute paucisymptomatic diverticulitis complicated by an enterovesical fistula, a situation that could explain the recent history of two sepsis due to urinary tract infections.

In our case and in that reported by Lee et al., liver cirrhosis appears as an influential comorbidity in the clinical evolution. Infections are frequent complications in cirrhotic patients and the risk of bacteraemia is about ten times higher than in non-cirrhotic patients [16]. This is due both to the immune dysfunction associated with cirrhosis and to the increased permeability of the intestinal mucosa [17], although in this case it is worth mentioning that anaerobic bacteria do not translocate easily and, to some extent, their presence helps to limit the translocation

Table 3

Main characteristics of reported cases of bacteremia caused by *Veillonella atypica*. The third column corresponds to the case presented in this publication.

	Case 1	Case 2	Case 3
Reference	Lee P; 2021 [10]	Ito Y; 2022 [11]	-
Age	31 y	70 y	50 y
Sex	Male	Female	Male
Comorbidities	Alcohol abuse Cirrhosis ANA + (1:1280) Alcoholic hepatitis	Heart failure Valvular heart disease DM2 HTA	Cirrhosis (alcoholic) DM2
Neoplasm	No	Yes (Kidney)	No
Clinical presentation	Fever Hydropic decompensation Abdominal pain	Fever Obstructive pyelonephritis post ureteroscopic biopsy	Fever Vomiting Complicated acute diverticulitis
Collections	No	No	Yes
Microbiological identification	MALDI-TOF	PCR	MALDI-TOF
Source	Abdominal	Urological	Abdominal/ Urological
Sensitivity	Ampicillin/sulbactam Clindamycin Imipenem/Meropenem Metronidazole	Meropenem Metronidazole Clindamycin	Penicillin Clindamycin Amoxicillin/clavulanate Metronidazole Piperacillin/Tazobactam No
Resistances	Penicillin	Benzylpenicillin Ampicillin Ampicillin/sulbactam Moxifloxacin	No
Treatment	Ceftriaxone IV 7d	Ceftriaxone IV 5d followed by cefditoren 200 mg 7d	Piperacillin/Tazobactam 3 days followed by Amoxicillin/clavulanate until 15d
Outcome	Died 3 months later	Resolution	Resolution

Table 4

Main clinical and microbiological characteristics of non-bacteremic *Veillonella atypica* infections reported in the literature.

Reference	Kumar et al. [15]	Crisafulli et al. [14]
Patient	55 year-old Woman	65-year-old male
Infection site	Retropharyngeal abscess	Pulmonary infection with empyema
Relevant history	No co-morbidities	Active smoker. Poor oral hygiene. 7–14 alcohol units per week
Source of infection	Oral cavity	Presumed oral cavity
Diagnosis method	Anaerobic culture from pus sample Confirmed by MALDI-TOF	Cultures of the sample obtained by bronchial aspirate. Confirmed by MALDI-TOF
Treatment	Surgery Antibiotic: Cloxacillin 500 mg intravenous (IV) four times a day, gentamicin 160 mg IV once a day and metronidazole 500 mg IV thrice a day for five days	Metronidazole (1500 mg/day) and piperacillintazobactam (13.5 g/day) for 3 weeks and then metronidazole 1500 mg/d 14 days more
Outcome	Symptomatic improvement	Resolution

of other more susceptible germs such as gram-negative bacteria [18]. Predisposing factors for the development of anaerobic bacteraemia have been broadly described [19]. Type 2 diabetes mellitus, recent pelvic surgery, neoplasms or treatment with quinolones are some factors that can be recognised in the three cases we analysed. None of the cases, including our patient, mentioned previous dental manipulation. Neither

was the use of steroids, the existence of neutropenia, hypogammaglobulinaemia or splenectomy. Previous studies that analysed bacteraemia due to *Veillonella* spp. detected the existence of active neoplasms (25 %) or the use of corticosteroids or immunosuppressants (15,6 %) as underlying predisposing conditions, although no risk factors were found in 21,8 % of the cases [4].

As mentioned above, there are up to twenty species within the *Veillonellaceae* family. Identification and distinction between species can be limited by conventional phenotypic techniques [20]. Thus, both the use of MALDI-TOF [21] and PCR (by 16S rRNA gene sequencing) allow for further discrimination when differentiating species.

There are no clear treatment guidelines due to the limited number of cases that have been published. Antimicrobial susceptibility has been studied in clinical isolates in different species of the genus *Veillonella*. In the case of *V. atypica*, resistance rates to penicillin (MIC ≥ 1 $\mu\text{g/mL}$) of 100 %, amoxicillin/clavulanic acid (MIC 16–32 $\mu\text{g/mL}$) of 6.7 % and metronidazole (MIC ≥ 8 $\mu\text{g/mL}$) of 40 % have been reported [22]. There are also no clear guidelines regarding the duration of treatment, and it should be adjusted to the severity of the disease. In all three cases, treatment with cephalosporins and amoxicillin-clavulanic acid was successful with a duration of 7, 12 and 15 days respectively.

To date, our case represents the third bacteremia due to *V. atypica*, an anaerobic germ that until recently was considered a harmless member of the mucosal microbiota, reported in the literature. The predisposing factors for infection are equivalent to other anaerobic microorganisms. Spectrophotometric techniques allow rapid detection of these species, while sequencing helps to identify isolates in cases where MALDI-TOF is insufficient. Further studies are needed to analyse resistance rates to optimise antimicrobial therapies in bacteria belonging to this genus, as well as to establish standardised treatment guidelines.

Ethical approval

Written consent was obtained from the patient to publish this case report and all accompanying clinical data and images.

Role of the funding source

This research did not receive any specific grant from funding agencies in the public, commercial, or not-for-profit sectors.

Author Agreement Statement

We the undersigned declare that this manuscript is original, has not been published before and is not currently being considered for publication elsewhere. We confirm that the manuscript has been read and approved by all named authors and that there are no other persons who satisfied the criteria for authorship but are not listed. We further confirm that the order of authors listed in the manuscript has been approved by all of us. We understand that the Corresponding Author is the sole contact for the Editorial process. He/she is responsible for communicating with the other authors about progress, submissions of revisions and final approval of proofs.

Informed Consent

Written informed consent was obtained from the patient for publication of this case report and any accompanying images or clinical details. A copy of the written consent is available for review by request.

CRedit authorship contribution statement

Miguel Franco Álvarez: Writing – review & editing, Writing – original draft, Conceptualization; **Jose Díaz Peromingo:** Validation, Supervision; **Adrián Domínguez Lago:** Writing – review & editing; **Mariño Fernández Cambeiro:** Writing – review & editing, Writing –

original draft; **Andrea Jardi Cuadrado:** Supervision, Conceptualization.

Declaration of Competing Interest

The authors declare the following financial interests/personal relationships which may be considered as potential competing interests: Miguel Franco Alvarez reports article publishing charges was provided by University Hospital of Santiago de Compostela. If there are other authors, they declare that they have no known competing financial interests or personal relationships that could have appeared to influence the work reported in this paper.

Acknowledgements

This research was supported by the University of Santiago de Compostela, which facilitated the publication of this case report through its funding and resources.

Data Availability

All relevant data from the clinical case are included in this article. Information on previously reviewed cases comes from publications available in the medical literature cited in the manuscript.

References

- [1] Zhou P, Manoil D, Belibasakis GN, Kotsakis GA. *Veillonellae*: beyond bridging species in oral biofilm ecology. *Front Oral Health* 2021;2:774115.
- [2] Giacomini JJ, Torres-Morales J, Dewhirst FE, Borisy GG, Mark Welch JL. Site specialization of human oral *Veillonella* species. *Microbiol Spectr* 2023;11. e04042-22.
- [3] Mashima I, Nakazawa F. The influence of oral *Veillonella* species on biofilms formed by *Streptococcus* species. *Anaerobe* 2014;28:54–61.
- [4] Cobo F, Aguilera-Franco M, Pérez-Carrasco V, García-Salcedo JA, Navarro-Marí JM. Bacteremia caused by *Veillonella parvula*: Two case reports and a review of the literature. *Anaerobe* 2024;88:102879.
- [5] Hirai J, Yamagishi Y, Kinjo T, Hagihara M, Sakanashi D, Suematsu H, et al. Osteomyelitis caused by *Veillonella* species: case report and review of the literature. *J Infect Chemother* 2016;22:417–20.
- [6] Pérez-Jacoite Asín MA, Fernández-Ruiz M, Serrano-Navarro I, Prieto-Rodríguez S, Aguado JM. Polymicrobial endocarditis involving *Veillonella parvula* in an intravenous drug user: case report and literature review of *Veillonella* endocarditis. *Infection* 2013;41:591–4.
- [7] Bhatti MA, Frank MO. *Veillonella parvula* meningitis: case report and review of *Veillonella* infections. *Clin Infect Dis* 2000;31:839–40.
- [8] Jeverica S, Kolenc U, Mueller-Premru M, Papst L. Evaluation of the routine antimicrobial susceptibility testing results of clinically significant anaerobic bacteria in a Slovenian tertiary-care hospital in 2015. *Anaerobe* 2017;47:64–9.
- [9] Maraki S, Mavromanolaki VE, Stafylaki D, Kasimati A. Surveillance of antimicrobial resistance in recent clinical isolates of Gram-negative anaerobic bacteria in a Greek University Hospital. *Anaerobe* 2020;62:102173.
- [10] Lee P, Fields BKK, Liang T, Dubé MP, Politano S. *Veillonella* bacteremia in alcoholic hepatitis. *Case Rep Hepatol* 2021;2021:9947213.
- [11] Ito Y, Nakayama H, Niitsu Y, Kaneko N, Otsuka M, Sawada Y, et al. The first case of *Veillonella atypica* bacteremia in a patient with renal pelvic tumor. *Anaerobe* 2022;73:102491.
- [12] Ngo JT, Parkins MD, Gregson DB, Pitout JDD, Ross T, Church DL, et al. Population-based assessment of the incidence, risk factors, and outcomes of anaerobic bloodstream infections. *Infection* 2013;41:41–8.
- [13] De Keukeleire S, Wybo I, Naessens A, Echahidi F, Van Der Beken M, Vandoorlaer K, et al. Anaerobic bacteraemia: a 10-year retrospective epidemiological survey. *Anaerobe* 2016;39:54–9.
- [14] Crisafulli E, Bernardinello N, Alfieri V, Pellegrino F, Lazzari C, Gnetti L, et al. A pulmonary infection by *Actinomyces odontolyticus* and *Veillonella atypica* in an immunocompetent patient with dental caries. *Respirol Case Rep* 2019;7:e00493.
- [15] Kumar P, Kumaresan M, Biswas R, Saxena SK. *Veillonella atypica* causing retropharyngeal abscess: a rare case presentation. *Anaerobe* 2023;81:102712.
- [16] Thulstrup AM, Sørensen HT, Schönheyder HC, Møller JK, Tage-Jensen U. Population-based study of the risk and short-term prognosis for bacteremia in patients with liver cirrhosis. *Clin Infect Dis* 2000;31:1357–61.
- [17] Bellot P, Francés R, Such J. Pathological bacterial translocation in cirrhosis: pathophysiology, diagnosis and clinical implications. *Liver Int* 2013;33:31–9.
- [18] Wiest R, Lawson M, Geuking M. Pathological bacterial translocation in liver cirrhosis. *J Hepatol* 2014;60:197–209.
- [19] Brook I. The role of anaerobic bacteria in bacteremia. *Anaerobe* 2010;16:183–9.
- [20] Sato T, Matsuyama J, Sato M, Hoshino E. Differentiation of *Veillonella atypica*, *Veillonella dispar* and *Veillonella parvula* using restricted fragment-length polymorphism analysis of 16S rDNA amplified by polymerase chain reaction. *Oral Microbiol Immunol* 1997;12:350–3.
- [21] Alcalá L, Marín M, Ruiz A, Quiroga L, Zamora-Cintas M, Fernández-Chico MA, et al. Identifying anaerobic bacteria using MALDI-TOF mass spectrometry: a four-year experience. *Front Cell Infect Microbiol* 2021;11:521014.
- [22] Ivanovna Shilnikova I. Species identification of clinical *Veillonella* isolates by MALDI-TOF mass spectrometry and evaluation of their antimicrobial susceptibility. *AJBLs* 2017;5:82.