

Specificity of *Stenurus* (Metastrongyloidea: Pseudaliidae) infections in odontocetes stranded along the north-west Spanish coast

A. Saldaña^a, C.M. López^{a,*}, A. López^{b,c}, P. Covelo^b, S. Remesar^a, N. Martínez-Calabuig^a, D. García-Dios^a, P. Díaz^a, P. Morrondo^a, P. Díez-Baños^a, R. Panadero^a

^a INVESAGA Group, Facultade de Veterinaria, Universidade de Santiago de Compostela, 27002, Lugo, Spain

^b Coordinadora para o Estudo Dos Mamíferos Mariños, CEMMA, 36380, Gondomar, Spain

^c Departamento de Biología & CESAM, Universidade de Aveiro, 3810-193, Aveiro, Portugal

ARTICLE INFO

Keywords:

Cetacean
Odontocetes
Parasites
Stenurus
Strandings
Galician coast

ABSTRACT

Parasites extracted from the lungs and the pterygoid sinus complex of 6 species of odontocetes stranded along the north-west Spanish coast (Northeast Atlantic) between 2009 and 2019 were morphologically identified. The samples belonged to 14 specimens, including 3 harbour porpoises, *Phocoena phocoena*, 6 short-finned pilot whales, *Globicephala macrorhynchus*, 1 long-finned pilot whale, *Globicephala melas*, 1 Risso's dolphin, *Grampus griseus*, 1 striped dolphin, *Stenella coeruleoalba* and 2 bottlenose dolphins, *Tursiops truncatus*. All animals (14/14) were infected by nematodes of the genus *Stenurus* spp.; moreover, two of them presented a mixed lung nematode infection by *Stenurus* spp. and *Halocercus* spp., and another two a mixed infection by *Stenurus* spp. and the trematode *Nasitrema* spp. in the pterygoid sinuses. The morphological characterization of the *Stenurus* specimens revealed the existence of three different species: *Stenurus minor*, present in the pterygoid sinuses of harbour porpoises with a mean intensity of 43.0 ± 9.0 ; *Stenurus globicephalae*, in the pterygoid sinuses of pilot whales and the Risso's dolphin (370.3 ± 579.4); and *Stenurus ovatus* infecting bottlenose and striped dolphins' lungs (47.7 ± 76.5). This is the first citation of *S. minor* and *S. ovatus* in odontoceti from the Galician coast. Nematodes of the genus *Stenurus* are frequent in odontocetes stranded along the north-west Spanish coast. A clear host-parasite association was observed between *S. minor* and the Phocoenidae family, between *S. globicephalae* and the subfamily Globicephalinae and between *S. ovatus* and subfamily Delphininae. Different trophic position and niche segregation may lead to different patterns of specificity.

1. Introduction

The Galician coast in north-western (NW) Spain is considered an important area for strandings due to its geographical characteristics, high cetacean biodiversity and abundance, and high fishery by-catch levels (López et al., 2002, 2003). Strandings provide valuable information not only on the presence and relative abundance of cetacean species but also on their anatomy, behaviour, and health status (Soares-Castro et al., 2019, García de los Ríos et al. 2021). However, only a very few studies have dealt on parasitic diversity and prevalence in marine mammals stranded in the area (Abollo et al., 1998; Reboredo-Fernández et al., 2014; Pons-Bordas et al., 2020).

Pseudaliids Railliet & Henry, 1909 (Nematoda: Metastrongyloidea) are found in the lungs, cranial sinuses, middle ear, and/or circulatory system of their odontocete hosts (Delyamure 1955). Little is known

about their life cycle or mode of transmission (Faulkner et al., 1998); moreover, data about the specificity of these nematodes are also scarce, mainly because host sampling is very difficult and experimental work virtually impossible (Pool et al., 2021). Pseudaliids have evolved and adapted to their host over thousands of years, and probably light infections pose no serious problems for otherwise healthy animals (Measures 2018).

Nine species of *Stenurus* have been reported in odontocetes throughout the world (Zylber et al., 2002). Most species are found in the middle ear, eustachian tube and cranial sinuses, while a few of them are found in bronchi and bronchioles (Measures 2001). The presence of *Stenurus*, often packed together in huge numbers, has been associated with obstruction of the auditive ducts and with osseous lesions, leading to the hypothesis that this infection could represent a potential factor in the stranding of Odontoceti (Delyamure 1955; Dailey and Stroud 1978;

* Corresponding author.

E-mail address: c.lopez@usc.es (C.M. López).

<https://doi.org/10.1016/j.ijppaw.2022.09.002>

Received 15 July 2022; Received in revised form 7 September 2022; Accepted 7 September 2022

Available online 13 September 2022

2213-2244/© 2022 The Authors. Published by Elsevier Ltd on behalf of Australian Society for Parasitology. This is an open access article under the CC BY-NC-ND license (<http://creativecommons.org/licenses/by-nc-nd/4.0/>).

Dailey and Walker 1978; Morimitsu et al., 1992).

In this study we identified the species of *Stenurus* collected from the lungs and the pterygoid sinus complex of 6 species of odontocetes found stranded along the Galician coastline (NW Spain). The intensity of infection in relation to the host's sex, size and species was also analyzed.

2. Materials and methods

2.1. Animals and samples

The parasitic samples collected from the pterygoid sinus complex and lungs of 14 odontocetes stranded along the Galicia coast (41° 54' 9" N, 8° 52' 25" W - 43°32'14"N 7°02'35"W) in the northeast Atlantic between February 2009 and August 2019 were analyzed. A total of eleven parasite samples were collected from the pterygoid sinuses of three harbour porpoises (*Phocoena phocoena* Linnaeus, 1758), six short-finned pilot whales (*Globicephala macrorhynchus* Gray, 1846), one long-finned pilot whale (*Globicephala melas* Trill, 1809), one Risso's dolphin (*Grampus griseus* Cuvier, 1812) and, three from the lungs of two bottlenose dolphins (*Tursiops truncatus* Montagu, 1821) and one striped dolphin (*Stenella coeruleoalba* Meyen, 1833) (Table 1).

Parasites were collected during the on-site necropsies by members of the *Coordinadora para o Estudo dos mamíferos Mariños* (CEMMA). Necropsies were carried out following standardized protocols (Kuiken and García 1991; Geraci and Lounsbury 1993). The abdominal and thoracic cavities were opened and lungs and other organs were inspected. The cranium was disarticulated from the trunk and the removal of soft parts allowed air sinuses to be examined (Fig. 1). All available parasites in the lungs and on the mucous coating of the pterygoid sinuses were collected and preserved in 70% ethanol at room temperature until further examination.

2.2. Morphological identification of parasites

All the worms extracted from the lungs and pterygoid sinuses were

Table 1

Odontoceti species, sex and body length (cm) along with stranding date and location.

	Host species (acronym)	Sex	Length	Stranding	
				Date	Location
1	<i>Phocoena phocoena</i> (PPH)	M	146	February 12, 2009	Vigo
2	<i>Phocoena phocoena</i> (PPH)	M	122	August 13, 2015	O Grove
3	<i>Phocoena phocoena</i> (PPH)	M	165	February 02, 2018	Malpica
4	<i>Globicephala macrorhynchus</i> (GMA)	M	457	October 07, 2013	Mañón
5	<i>Globicephala macrorhynchus</i> (GMA)	F	365	October 07, 2013	Mañón
6	<i>Globicephala macrorhynchus</i> (GMA)	F	247	October 07, 2013	Mañón
7	<i>Globicephala macrorhynchus</i> (GMA)	M	397	October 07, 2013	Mañón
8	<i>Globicephala macrorhynchus</i> (GMA)	F	371	October 07, 2013	Mañón
9	<i>Globicephala macrorhynchus</i> (GMA)	M	344	August 20, 2019	Foz
10	<i>Globicephala melas</i> (GME)	F	440	September 30, 2017	O Grove
11	<i>Grampus griseus</i> (GGR)	M	–	November 29, 2017	A Guarda
12	<i>Stenella coeruleoalba</i> (SCO)	M	210	March 26, 2015	Oia
13	<i>Tursiops truncatus</i> (TTR)	M	286	August 29, 2015	Porto do son
14	<i>Tursiops truncatus</i> (TTR)	M	328	October 05, 2018	Cee

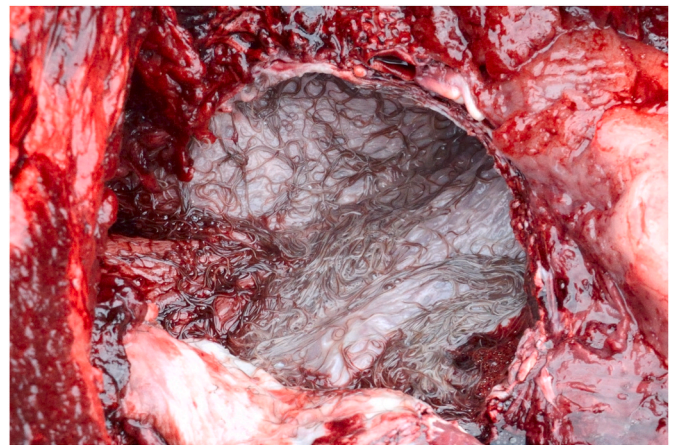

Fig. 1. Nematodes found in the pterygoid sinuses during the necropsy of a short-finned pilot whale (*Globicephala macrorhynchus*).

counted, measured, and classified by stage and sex using an Olympus SZX7 binocular stereomicroscope at 30x. Those that were preliminary identified as *Stenurus* spp. were classified as mature or immature according to the sclerotization of the spicules (males) and gravidity (females).

For specific identification all the specimens were cleared with Amann's lactophenol with 0.01% blue cotton and mounted for morphological identification using an Olympus CX43 microscope, following the keys of Baylis and Daubney (1925), Baylis (1928) and Delyamure (1955). Measurements were taken using a digital camera (Olympus EP50) attached to a compound microscope with Olympus software.

2.3. Statistical analysis

All the statistical analysis were performed with R statistical package (R v.4.12; R Core Team, 2020). The significance was set at $P < 0.05$. The nonparametric Wilcoxon rank sum exact test was used to compare the intensity of infection in relation to the host's species and sex. The one-tailed Spearman correlation test was used to relate worm abundance with host body length.

Bipartite multigraph was created with `bmgraph()` function from multigraph package (Ostojic, 2021) and then modified with Inkscape v.1.2 to add the image of the females of the three species of *Stenurus*.

3. Results

All individuals (14/14) examined were infected with nematodes of the family Pseudaliidae. All the specimens found in the pterygoid sinuses belonged to the genus *Stenurus*, whereas two out of the three samples of nematodes collected from the lungs presented mixed infections by *Stenurus* and *Halocercus* (Table 2). Moreover, two of the short-finned pilot whales harboured in its pterygoid sinuses a mixed infection by *Stenurus* and a trematode Digenea of the genus *Nasitrema* (Family Brachycladiidae).

When comparing the number of *Stenurus* collected in the different species, the Wilcoxon test showed that short-finned pilot whales were more intensely infected than the other odontocete species ($W = 41$; $P = 0.0293$). Moreover, the Spearman correlation test showed a positive and significant correlation between the parasite burden and the host length ($S = 128$; $R = 0,719$; $P = 0.005$). On the contrary, no differences in the intensity of infections were found taking into consideration the sex of the animals ($W = 21$; $P = 0.9451$).

All the specimens of the *Stenurus* genus were classified as mature with a clear predominance of females (85.2%) over males (14.8%), both in the pterygoid sinuses (ratio 4.6:1) and in the lungs (ratio 3.2:1), with

Table 2

Total number of *Stenurus* spp. recovered from the pterygoid sinuses (PS) and lungs (L) of Odontoceti stranded in the Galician coast (2009–2019). Number and length (mm) of females and males and sex ratio (F:M).

	Host	<i>Stenurus</i> spp.	n	Location	Females		Males		F:M
					n	Length	n	Length	
1	PPH ^a	<i>S. minor</i>	52	PS	37	17.7 ± 3.1	15	16.7 ± 3	2.5:1
2	PPH ^a	<i>S. minor</i>	34	PS	17	19.9 ± 2.9	17	16.3 ± 1.9	1:1
3	PPH ^a	<i>S. minor</i>	43	PS	36	22.9 ± 2.1	7	19.3 ± 2.4	5.1:1
4	GMA ^b	<i>S. globicephalae</i> ^g	496	PS	437	38.3 ± 3.7	59	19.2 ± 4.5	6.8:1
5	GMA ^b	<i>S. globicephalae</i>	189	PS	153	38.1 ± 4.2	36	28.4 ± 4.5	3.6:1
6	GMA ^b	<i>S. globicephalae</i>	18	PS	15	38.3 ± 8.6	3	22.6 ± 6.6	4.3:1
7	GMA ^b	<i>S. globicephalae</i> ^g	1761	PS	1585	29 ± 7.6	176	20.3 ± 4.4	7.2:1
8	GMA ^b	<i>S. globicephalae</i>	121	PS	100	36.1 ± 6.8	21	26.1 ± 2.7	4.8:1
9	GMA ^b	<i>S. globicephalae</i>	110	PS	99	26.6 ± 7	11	19.5 ± 5	9.0:1
10	GME ^c	<i>S. globicephalae</i>	107	PS	84	44.2 ± 2.6	23	25.2 ± 3.9	3.7:1
11	GGR ^d	<i>S. globicephalae</i>	161	PS	121	39.7 ± 3.4	40	20.7 ± 2.6	3.0:1
12	SCO ^e	<i>S. ovatus</i> ^h	1	L	1	23 ± 0	0	–	1:0
13	TTR ^f	<i>S. ovatus</i> ^h	6	L	4	14.5 ± 6.4	2	10 ± 0	2:1
14	TTR ^f	<i>S. ovatus</i>	136	L	118	17.8 ± 6	18	9.4 ± 1.9	6.6:1
Total			3235	–	2807	29.0 ± 4.6	428	19.5 ± 3.3	4.3:1

^a *Phocoena phocoena*.

^b *Globicephala macrorhynchus*.

^c *Globicephala melas*.

^d *Grampus griseus*.

^e *Stenella coeruleoalba*.

^f *Tursiops truncatus*.

^g Mixed infection with *Nasitrema* sp.

^h Mixed infection with *Halocercus* sp.

an overall ratio of 4.3:1 (Table 2). All mature females of *Stenurus* spp. harboured first stage larvae in their uterus (Fig. 2B and D). The mean body length of *Stenurus* spp. was significantly shorter in males (19.5 ± 3.3 mm) than in females (29 ± 4.6).

Three different species of *Stenurus* were morphologically identified: *Stenurus minor* (Kuhn, 1829) Baylis and Daubney (1925); *Stenurus globicephalae* Baylis and Daubney (1925) and *Stenurus ovatus* (von Linstow, 1910) Baylis and Daubney (1925).

All the parasites found in the pterygoid sinuses of harbour porpoises corresponded to the species *S. minor*. The male of this species is characterized by a well-developed undivided bursa (Fig. 2A) with broad spicules (0.14 ± 0.011 mm long). The posterior end of the female has a finger-shaped cuticular process on the anterior lip of the vulva (Fig. 2B). Intensity of infection by *S. minor* ranged from 34 to 52 (mean 43 ± 9), with a female to male ratio of 2.3:1 (69.8% females). The female average length (20.2 ± 2.7 mm) was higher than male's (17.4 ± 2.4 mm).

Short and long-finned pilot whales and the Risso's dolphin harboured at their pterygoid sinuses the species *Stenurus globicephalae*. The male of this species has the bursa divided into three lobes (Fig. 2C) and the spicules are 0.15 ± 0.010 long; the female has one or multiple spherical cuticular swellings on the anterior and posterior lips of the vulva (Fig. 2D). Mean intensity of infection by *S. globicephalae* was 370.3 ± 579.4 with a sex ratio of 5.3:1 (85.8% females). In this species the females measured 36.3 ± 5.5 mm and the males 22.7 ± 4.3 mm. The ratio of the mixed infection of *S. globicephalae* and *Nasitrema* sp. was 1128.5:1.

Finally, *S. ovatus* was recorded in the lungs of three dolphins. The posterior end of the male showed a bursa divided into lobes and three long rays, the dorsal one being the longest, ending in a forked tip. The spicules were 0.17 ± 0.012 mm long (Fig. 2E). The female presents a pair of conical terminal processes and a cuticular swelling between the anus and the vagina (Fig. 2F). The mean intensity of *S. ovatus* was 47.6 ± 76.5 with a sex ratio of 3.2:1 (86% females). *S. ovatus* female's average length was 18.4 ± 4.2 mm and the average length of the males was 9.7 ± 0.95 mm. The ratio of the mixed infection of *S. ovatus* and *Halocercus* sp. was 1:3.25.

The length of *Stenurus* spp. were directly proportional to the size of their host but the differences were not significant (S = 220; R = 0,516; P

= 0.062).

4. Discussion

Pseudaliid nematodes are common parasites of the respiratory tract and the pterygoid sinuses of delphinids and porpoises in both hemispheres (Lehnert et al., 2005; Tomo et al., 2010). All the odontoceti included in this study were infected by pseudaliid nematodes of the genus *Stenurus*. In addition, mixed infections with other pseudaliid, *Halocercus delphini* Baylis and Daubney (1925), were found in the lungs of one striped and bottlenose dolphins; mixed infection with the trematode Digenea *Nasitrema* was detected in the pterygoid sinuses of two short-finned pilot whales.

Despite the small sample size, there is strong evidence that *Stenurus* is the most prevalent parasite in the pterygoid sinuses and lungs of odontoceti in the northwestern Spanish Atlantic coast. Two out of the three lung parasitic samples contained *Halocercus delphini*, so a high prevalence of this lungworm could also be expected. In a previous study carried out by Abollo et al. (1998) in the same area *Stenurus globicephalae* was identified with a prevalence of 50% in the air sinuses of long-finned whales, whereas the genus *Halocercus* was found in the lungs of harbour porpoises (25%), bottlenose (10%), striped (25%) and common (18%) dolphins.

Three out of the nine species included in the genus *Stenurus* were morphologically identified from the six odontoceti species stranded in the Galician coast: *S. minor*, *S. ovatus* and *S. globicephalae*, making this the first description of *S. minor* and *S. ovatus* in Galician waters. A recent study (Pool et al., 2021) has shown that the species identification following the morphological descriptions by Delyamure (1955) for *Stenurus* spp. was congruent with the molecular analysis of the ITS2 barcoding region of ribosomal DNA so, it can be assumed that the morphological identification for those species is reliable.

A clear pattern of host specificity was observed for the *Stenurus* species, with *S. minor* showing a specificity for Phocoenidae (harbour porpoises), *S. globicephalae* for Globicephalinae (pilot whales and Risso's dolphin), and *S. ovatus* for Delphininae (bottlenose and striped dolphins) (Fig. 3).

The host-parasite associations observed in the northeastern Atlantic




Fig. 2. (A–B) *Stenurus minor*: posterior end of a male (A) with an undivided bursa and broad spicules and of a female (B) with a finger-shaped cuticular process on the anterior lip of the vulva (➔) and first stage larvae (L1) in the uterus (⇨). (C–D) *Stenurus globicephalae*: posterior end of a male (C) and a female (D) with multiple cuticular swellings (➔) and L1 in the uterus (⇨). (E–F) *Stenurus ovatus*: posterior end of a male (E) with a divided bursa showing three rays and a female (F) showing a conical terminal process (➔) and a cuticular swelling (⇨).

waters match with those found by Pool et al. (2021) in western Mediterranean, who observed that both *S. ovatus* and *Halocercus delphini* were restricted to the clade of the Delphininae, and *S. globicephalae* to the clade of the Globicephalinae. In addition, our findings also support a clear association between *S. minor* and Phocoenidae.

Marine mammal parasites constitute valuable indicators of host habitat use, diet, migration, and population dynamics (Balbuena and Raga, 1994). Pool et al. (2021) found a weak but significant association between prey overlap and lungworm species similarity. In our study, predominantly teuthophagous species like pilot whales and Risso's dolphins were infected by *S. globicephalae*, whereas piscivorous species such as the bottlenose dolphin and species with a mixed diet like the

striped dolphin, harboured *S. ovatus*. However, harbour porpoises which have a mixed diet harboured *S. minor*. Méndez-Fernández et al. (2013) confirmed the existence of a niche segregation of these odontocete species in our study area, with the harbour porpoise in the highest trophic level. Pierce et al. (2010) affirmed that even though the three main cetaceans in Galician waters (porpoises, bottle nose and common dolphins) feed primarily on fish, there are differences in the species of prey eaten and also differences in habitat use to avoid food competition and, in the case of porpoises, it is possible that they do not use areas frequented by bottlenose dolphins in order to avoid aggressive interactions (Ross and Wilson 1996; Santos and Pierce 2003). Therefore, trophic specialization and differences in the niche occupied for each cetacean




Fig. 3. Bipartite multigraph relating the three *Stenurus* species with their hosts. The width of the links (gray arrows) represents the mean parasitic load on each host.

species may lead to different patterns of parasite specificity.

In relation to the anatomical localization, most *Stenurus* species occur in the middle ear, eustachian tube and cranial sinuses, whereas a few species have been reported to occur in bronchi and bronchioles (Measures, 2001). In this study, *S. minor* and *S. globicephalae* were found at the pterygoid sinuses and only *S. ovatus* was observed in the lungs. *Stenurus minor* is commonly found in the cranial sinuses and tympanic cavities of Phocoenidae in both hemispheres (Jefferson 1988; Corcuera et al., 1995; Lehnert et al., 2005, 2017). *S. globicephalae* has been described from the tympanic cavity, pterygoid sinuses, cranial sinuses and in the lungs of Globicephalinae from both hemispheres (Odell et al., 1980; Gibson et al., 1998; Fernández et al., 2003; Lehnert et al., 2010, 2017; Pool et al., 2021). *S. ovatus* has been documented in the lungs of Delphinidae (Pool et al., 2021).

In this study, short-finned pilot whales had higher infection levels than the other odontocetes, which could indicate a good adaptation between this species and *S. globicephalae*. Moreover, there were also differences in the length of the different species of *Stenurus*, being *S. globicephalae* the longest, followed by *S. minor* and *S. ovatus*. This agrees with Pool et al. (2021) who also recorded the largest nematodes in the same host species that had the highest parasite burden. On the contrary, Faulkner et al. (1998) found an inverse relationship between the intensity of *S. minor* infection and mean worm length, which was suggestive to a crowding effect. The one-tailed Spearman correlation test was used to relate worm abundance with host body length, since larger hosts could have more infection opportunities due to higher food consumption (Measures 2001).

Some adult pulmonary pseudaliids stimulate none or little inflammatory response in bronchi or bronchioles, but larvae in alveoli can cause a subacute purulent focal pneumonia (Cowan 1967; Dailey and Stroud 1978; Measures 2001). Moreover, no gross lesions associated with the presence of numerous *S. minor* in the cranial sinuses were observed by Faulkner et al. (1998). According to different authors, Pseudaliids located in the cranial sinuses and middle ear provoke minor hemorrhage, mild to moderate nonsuppurative chronic inflammation and thickening of the sinus mucosal lining, rarely purulent sinusitis (Delyamure 1955; Measures 2001). However, Zylber et al. (2002) detected the presence of abundant lungworms, identified as *S. globicephalae* in the cranial air sinuses of a false killer whale (*Pseudorca crassidens* Owen, 1846) which revealed loss of osseous mass with the disappearance of the left zygomatic arch, and the left jaw had three osseous fenestrations in the region related to the organ of acoustic reception. These lesions supported the hypothesis of these authors that this infection was related to the stranding. In our study, it has not been possible to establish a relationship between the presence of *Stenurus* in the host and the strandings. However, its presence in the pterygoid sinuses and in the lungs could induce lesions given a stressful situation, causing discomfort to the host.

In conclusion, nematodes of the genus *Stenurus* are frequent in odontocetes stranded along the north-west Spanish coast, showing a clear host-parasite association propitiated by niche segregation and trophic position.

Funding

Parasitological identification was funded by the Program for consolidating and structuring competitive research groups (ED431C 2019/04, Xunta de Galicia, Spain).

Declaration of competing interest

None.

Acknowledgements

We thank CEMMA volunteers for their help with sample collection.

The Galician stranding network is supported by the regional government Xunta de Galicia/Dirección Xeral de Patrimonio Natural, that also provided the legal permits for the management of cetacean species and the collection of biological samples.

References

- Abollo, E., Lopez, A., Gestal, C., Benavente, P., Pascual, S., 1998. Long-term recording of gastric ulcers in cetaceans stranded on the Galician (NW Spain) coast. *Dis. Aquat. Org.* 32, 71–73.
- Balbuena, J.A., Raga, J.A., 1994. Intestinal helminths as indicators of segregation and social structure of pods of long-finned pilot whales (*Globicephala melas*) off the Faeroe Islands. *Can. J. Zool.* 72, 443–448.
- Baylis, H.A., Daubney, R., 1925. A revision of the lung-worms of cetacea. *Parasitology* 17, 201–215.
- Baylis, H.A., 1928. LXI. –Note on *Stenurus ovatus* (v. Linstow), a little-known lungworm of Cetacea. *Ann. Mag. Nat. Hist.* 2, 464–466.
- Corcuera, J., Monzón, F., Aguilar, A., Borrell, A., Raga, J.A., 1995. Life history data, organochlorine pollutants and parasites from eight Burmeister's porpoises, *Phocoena spinipinnis*, caught in northern Argentine waters. In: Bjørge, A., Donovan, G.P. (Eds.), *Biology of the Phocoenids*. International Whaling Commission, Cambridge, pp. 365–372.
- Cowan, D.F., 1967. Helminth parasites of the pilot whale *Globicephala melaena* (Traill 1809). *J. Parasitol.* 53, 166.
- Dailey, M.D., Stroud, R., 1978. Parasites and associated pathology observed in cetaceans stranded along the Oregon coast. *J. Wildl. Dis.* 14, 503–511.
- Dailey, M.D., Walker, W.A., 1978. Parasitism as a factor (?) in single strandings of southern California cetaceans. *J. Parasitol.* 64, 593–596.
- Delyamure, S.L., 1955. Helminthofauna of Marine Mammals (Ecology & Phylogeny). *Izdatel'stvo Akademii Nauk SSSR, Moscow*. Translated by Israel Program for Scientific Translation, Jerusalem, 1968.
- Faulkner, J., Measures, L.N., Whoriskey, F.G., 1998. *Stenurus minor* (Metastrongyloidea: pseudaliidae) infections of the cranial sinuses of the harbour porpoise, *Phocoena phocoena*. *Can. J. Zool.* 76, 1209–1216.
- Fernández, M., Agustí, C., Aznar, F., Raga, J., 2003. Gastrointestinal helminths of Risso's dolphin *Grampus griseus* from the western Mediterranean. *Dis. Aquat. Org.* 55, 73–76.
- García de los Ríos, A., Soler, M., Arencibia, A., López, A., Covelo, P., Martínez, F., Sánchez, C., García, N., Ramírez, G., 2021. Comparative anatomy of the nasal cavity in the common dolphin *Delphinus delphis* L., striped dolphin *Stenella coeruleoalba* M. and pilot whale *Globicephala melas* T.: a developmental study. *Animals* 11, 441.
- Geraci, J.R., Lounsbury, V.J., 1993. Cetacean/pinniped necropsy report. In: Yates, S.N. (Ed.), *Marine Mammals Ashore. A Field Guide for Strandings*. A&M University Sea Grant Publication, Texas, p. 349.
- Gibson, D.I., Harris, E.A., Bray, R.A., Jepson, P.D., Kuiken, T., Baker, J.R., Simpson, V.R., 1998. A survey of the helminth parasites of cetaceans stranded on the coast of England and Wales during the period 1990–1994. *J. Zool.* 244, 563–574.
- Jefferson, T.A., 1988. *Phocoenoides dalli*. *Mammalia* 319, 1–7.
- Kuiken, T., García, M., 1991. Standard protocol for the basic postmortem examination and tissue sampling of small cetaceans. In: Kuiken, T., Hartmann, M.G. (Eds.), *Cetacean Pathology: Dissection Techniques and Tissue Sampling*. Proc 1st ECS Workshop on Cetacean Pathology. ECS 17 (Special Issue). The Netherlands, Leiden, pp. 30–39.
- Lehnert, K., Raga, J., Siebert, U., 2005. Macroparasites in stranded and by caught harbour porpoises from German and Norwegian waters. *Dis. Aquat. Org.* 64, 265–269.
- Lehnert, K., von Samson-Himmelstjerna, G., Schaudien, D., Bleidorn, C., Wohlsein, P., Siebert, U., 2010. Transmission of lungworms of harbour porpoises and harbour seals: molecular tools determine potential vertebrate intermediate hosts. *Int. J. Parasitol.* 40, 845–853.
- Lehnert, K., Randhawa, H., Poulin, R., 2017. Metazoan parasites from odontocetes off New Zealand: new records. *Parasitol. Res.* 116, 2861–2868.
- López, A., Santos, M.B., Pierce, G.J., González, A.F., Valeiras, X., Guerra, A., 2002. Trends in strandings and by-catch of marine mammals in north-west Spain during the 1990s. *J. Mar. Biol. Assoc. UK.* 82, 513.
- López, A., Pierce, G., Santos, M.B., Gracia, J., Guerra, A., 2003. Fishery by-catches of marine mammals in Galician waters: results from on-board observations and an interview survey of fishermen. *Biol. Conserv.* 111, 25–40.
- Measures, L.N., 2001. Lungworms of marine mammals. In: Samuel, W.M., Pybus, M.J., Kocan, A.A. (Eds.), *Parasitic Diseases of Wild Mammals*. Iowa State University Press, Ames, pp. 279–300.
- Measures, L.N., 2018. Helminths and parasitic arthropods. In: Gulland, F.M.D., Dierauf, L.A., Whitman, K.L. (Eds.), *CRC Handbook of Marine Mammal Medicine*, third ed. CRC Press, Boca Raton, pp. 471–497.
- Méndez-Fernández, P., Pierce, G.J., Bustamante, P., Chouvelon, T., Ferreira, M., González, A.F., López, A., Read, F.L., Santos, M.B., Spitz, J., Vingada, J.V., Caurant, F., 2013. Ecological niche segregation among five toothed whale species off the NW Iberian Peninsula using ecological tracers as multi-approach. *Mar. Biol.* 160, 2825–2840.
- Morimitsu, T., Kawano, H., Torihara, K., Kato, E., Koono, M., 1992. Histopathology of Eighth cranial nerve of mass stranded dolphins at Goto Islands, Japan. *J. Wildl. Dis.* 28, 656–658.
- Odell, D.K., Asper, E.D., Baucom, J., Cornell, L.H., 1980. A recurrent mass stranding of the false killer whale, *Pseudorca crassidens*, in Florida. *Fish. Bull.* 78, 171–177.

- Ostoic, J., 2021. Algebraic Analysis of Social Networks: Models, Methods and Applications Using R. Wiley Series in Computational and Quantitative Social Science. Wiley, Oxford, pp. 235–238.
- Pierce, G., Caldas, M., Cedeira, J., Santos, M., Llavona, Á., Covelo, P., Martínez, G., Torres, J.M., Sacau, M., López, A., 2010. Trends in cetacean sightings along the Galician coast, north-west Spain, 2003–2007, and inferences about cetacean habitat preferences. *J. Mar. Biol. Assoc. UK* 90, 1547–1560.
- Pons-Bordas, C., Hazenberg, A., Hernández-González, A., Pool, R.V., Covelo, P., Sánchez-Hermosín, P., López, A., Saavedra, C., Fraija-Fernández, N., Fernández, M., Aznar, F. J., 2020. Recent increase of ulcerative lesions caused by *Anisakis* spp. in cetaceans from the north-east Atlantic. *J. Helminthol.* 94, 1294.
- Pool, R., Romero-Rubira, C., Raga, J.A., Fernández, M., Aznar, F.J., 2021. Determinants of lungworm specificity in five cetacean species in the western Mediterranean. *Parasites Vectors* 14, 196.
- Reboredo-Fernández, A., Gómez-Couso, H., Martínez-Cedeira, J.A., Cacciò, S.M., Ares-Mazás, E., 2014. Detection and molecular characterization of *Giardia* and *Cryptosporidium* in common dolphins (*Delphinus delphis*) stranded along the Galician coast (Northwest Spain). *Vet. Parasitol.* 202, 132–137.
- Ross, H.M., Wilson, B., 1996. Violent interactions between bottlenose dolphins and harbour porpoises. *Proc. R. Soc. Lond. Ser. B Biol. Sci.* 263, 283–286.
- Santos, M.B., Pierce, G.J., 2003. The diet of harbour porpoise (*Phocoena phocoena*) in the northeast Atlantic. *Oceanogr. Mar. Biol. Annu. Rev.* 41, 355–390.
- Soares-Castro, P., Araújo-Rodrigues, H., Godoy-Vitorino, F., Ferreira, M., Covelo, P., López, A., Vingada, J., Eira, C., Santos, P.M., 2019. Microbiota fingerprints within the oral cavity of cetaceans as indicators for population biomonitoring. *Sci. Rep.* 9.
- Tomo, I., Kemper, C.M., Lavery, T.J., 2010. Eighteen-year study of south Australian dolphins shows variation in lung nematodes by season, year, age class, and location. *J. Wildl. Dis.* 46, 488–498.
- Zylber, M.I., Failla, G., Le Bas, A., 2002. *Stenurus globicephalae* Baylis et Daubney, 1925 (Nematoda: pseudaliidae) from a False Killer Whale, *Pseudorca crassidens* (Cetacea: Delphinidae), Stranded on the Coast of Uruguay. *Mem. Inst. Oswaldo Cruz* 97, 221–225.